

## Assesment of caspase 1 activation in L-arginine induced inflammation resulting from necrosis, in rats' hepatocytes

Agnieszka Pedrycz<sup>1</sup>, Piotr Siermontowski<sup>2</sup>, Marcin Orłowski<sup>3</sup>, Piotr Baran<sup>4</sup>

<sup>1</sup>Department of Histology and Embryology Medical University in Lublin

<sup>2</sup>Department of Maritime & Hyperbaric Medicine, Military Institute of Medicine, Gdynia

<sup>3</sup>Centrum of Diagnosis and Therapy of Digestive System's Diseases Gdańsk

<sup>4</sup>Ward of Gyneacology, Independent Public Health Care in Garwolin

---

### Abstract

In our previous studies we analyzed the influence of nitric oxide (NO) on rats' liver.

The results showed that L-arginine as a nitric oxide precursor doesn't induce apoptosis of hepatocytes. In present study we was observing expression of caspase 1, an enzyme activated during inflammation results from necrosis.

The rats used in this experiment were divided into 2 equal groups. Experimental: rats received per os L-arginine 40mg/kg body weight, every other day for 2 weeks and were decapitated after 3 weeks of the experiment. Control rats received per os 2ml of distilled water every other day for 2 weeks and were decapitated after 3 weeks of the experiment.

Specimens of the liver taken after decapitation were examined in immunohistochemical way using standard three step method to detect immunolocalization of caspase 1. The results of immunohistochemical examinations were subjected to qualitative evaluation taking into account the intensity of colour reaction at the antigen-antibody site in rat liver examined in individual groups. The quantitative evaluation was using the Analysis-pro software. The surface area of cells with positive reaction (+) was calculated.

The quantitative evaluation of caspase 1 expression showed that the area occupied by positive caspase 1 reaction in the rat liver of the experimental group was comparable to that in the control group. The study shows that L-arginine as a donor of exogenous nitric oxide did not have a necrotic effect on the hepatocytes of the rats.

*Keywords:* liver, necrosis, L-arginine, caspase 1

---

### Introduction

In our previous studies we analyzed the influence of nitric oxide (NO) on rats' liver. We were interested in expression of proteins activated during L-arginine induced apoptosis [1]. The results showed that L-arginine as a nitric oxide precursor induced apoptosis of hepatocytes comparably to control. There was no positive immunohistochemical reaction significantly different from that in control for any proteins involved in the transmission of apoptotic signal.

L-arginine is a precursor of NO. Nitric oxide is one of the most effective "free radical scavengers". It reacts with peroxide radicals forming harmless compounds.

However, its too high concentrations make it harmful. NO combines with O<sub>2</sub> and converts into pernitrate which initiates the process of lipid peroxidation.

In present study we was observing expression of caspase 1, an enzyme activated during inflammation results from necrosis. Necrosis apart from apoptosis is the most common cell death.

This death is accidental, caused by an exogenous harmful factor which blocks the life processes of the cell (e.g. respiration or production of high-energy compounds). It is a pathological, passive, catabolic, and degenerative process

which results in a substantial loss of many cells in the tissue and in an inflammatory reaction [2,3].

The necrotic cell swells because its membrane becomes more permeable for water. The smooth and rough endoplasmic reticulum space widens, mitochondria become oedematous [4,5]. The plasmatic membranes undergo perforation. The cell ruptures pouring its content in the intercellular space. The necrotic focus develops, which is filled with lymphocytes, neutrophils and macrophages involved in the inflammatory process. DNA is cleaved into fragments of various length. Proinflammatory caspases are activated in this process, especially caspase 1, analyzing in present study.

### Material and methods

The study material consisted of 16 white Wistar female rats aged 2.5-3 months. The rats were divided into 2 equal groups. The rats in group I - were administered L-arginine through the stomach tube every other day in the amount of 40 mg/kg body weight 7 x for 2 weeks and were decapitated after 3 weeks of the experiment. The rats in group II - received 2 ml of distilled water through the stomach tube every other day for 2 weeks and were decapitated after 3 weeks of the experiment.

After decapitation the hepatic specimens collected for immunohistochemical examinations were fixed in 10% formalin, dehydrated in the alcohol series and embedded in paraffin blocks. The blocks were cut into 5 $\mu$ m-sections, which were placed on the silanized glasses. Two specimens from liver collected from each animal were used. Next paraffin was removed in xylene and in a graded alcohol series. The specimens were subjected to thermal preparation in the acid medium. Next endogenous peroxidase was blocked by incubation in H<sub>2</sub>O<sub>2</sub>. After that the specimens were incubated with rabbit primary antibody caspase 1 (Lab Vision RB-9259-PO) in 1% TBS/BSA, dilution 1/100. Then the DakoCytomation kit was used for immunohistochemical reactions, which included: biotinylated secondary antibody, streptavidin conjugated with horse-radish peroxidase and AEC substrate. After chromotogen staining the specimens were placed in the haematoxylin solution and rehydrated. The photographic documentation was prepared using the computer-guided Colour Video Camera CCD-IRIS(Sony).

The results of immunohistochemical examinations were subjected to qualitative evaluation and quantitative evaluation using the Analysis-pro software, version 3 (Soft Imaging System GmbH, Germany). The microscopic images, magnification x125 were analysed assessing the protein expression in 3 randomly chosen areas, 781193.35 $\mu$ m<sup>2</sup>, each. The surface area of cells with positive reaction (+) was calculated.

The results were presented as means and standard deviation of the mean using the ANOVA, t-student tests. 5% error risk and statistical significance at  $p \leq 0.05$  were accepted.

## Results

Color reaction in places, where active caspase 1 was detected was weak. There wasn't too many places with reaction antigen-antibody. Qualitative and quantitative evaluation revealed weak caspase 1 reaction in the rat liver in experimental group, which was comparable with the control (Fig.1), (Table 1).

## Discussion

The process of apoptosis was divided into 3 phases: decisive, executive and degradation ones [6].

The executing phase is irreversible. Its relevant elements are cysteine proteases from the interleukin -1-beta-converting enzyme (ICE) family called the caspase family [7]. The caspases digest proteins behind asparaginian residue using one of their cysteine residues [8], hence their name – cysteine-dependent asparaginian specific proteases. These enzymes are present in the cell in their inactive form (proenzymes, zymogenes, pro-caspases) and are activated

Fig.1. CONTROL GROUP. Very weak caspase 1 reaction in the rat liver. AEC+H staining. Magnification about x 140.

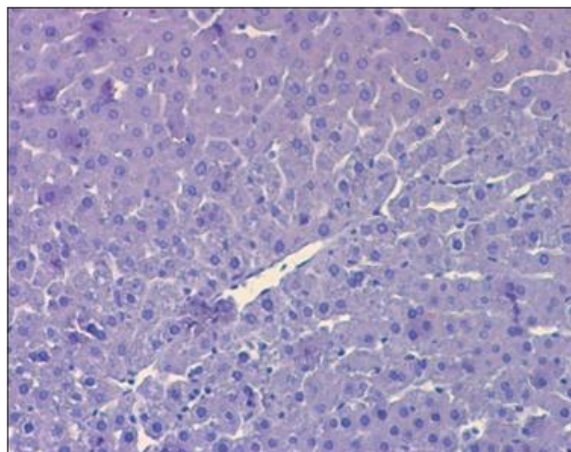


Table 1. Mean area occupied by caspase 1 reaction in the rat liver in all groups. Statistical significance of differences ONE WAY ANOVA test.

Group	Control	Experimental	ONE WAY ANOVA
Caspase 1	221.35 $\mu$ m <sup>2</sup> +/-203.14	209.35 $\mu$ m <sup>2</sup> +/-162.90	p=0.20

during apoptosis. They activate one another and other enzymes [9]. Their action results in the damage to protein cytoskeleton, topoisomerases, kinases, nuclear membrane, and poly ADP-ribose polymerase (PARP-responsible for DNA repair) proteins; the damage to nuclear enzymes; DNA fragmentation between individual nucleosomes.

Caspases are also involved in the activation of transglutaminase and kinases (responsible for biochemical modifications in cellular membranes); thanks to that the apoptotic body has a dense membrane, which prevents the outflow of the content and simultaneously is recognized by the adjacent cells and phagocytosed by them [10].

To date 14 caspases have been discovered and described [11]. They were divided into initiating, effector and proinflammatory caspases.

Caspase 1 /ICE (interleukin-1 $\beta$  converting enzyme) is one of the inflammation markers. This inflammation results from necrosis. The proinflammatory caspases include apart from Caspase 1, Caspase 4/ICEII, Ich-2 (ICE and ced-3 homologue-1), Caspase 5/ICE III/TY(TY protease), Caspase 11. They are mainly associated with proteolytic processing of proinflammatory cytokines: pro-IL-1 $\beta$ , pro-IL-18 and their role in the process of apoptosis is questioned [12]. However, these caspases are involved in necrosis which leads to inflammation.

In all stages of the present study, the level of caspase 1, involved in the process of inflammation resulting from

necrosis, was examined immunohistochemically. Caspase 1 was always at the level comparable with that in control, which is likely to indicate the lack of inflammation and marked predominance of apoptosis over potential necrosis. Moreover, necrosis was not confirmed by hepatic images observed under light and electron microscope.

## References

1. Pedrycz A., Zwierzyńska E., Siermontowski P., Orłowski M. Caspase 8 - biomarker of extrinsic pathway of apoptosis in exogenous nitric oxide (NO) - induced death of rats' hepatocytes. *Curr. Probl. Psychiatry*, 2011; 12: 356-359.
2. Jendryczko A. Apoptoza-kontrolowana śmierć komórki. *Post Nauk Med*, 1995; 8: 267-270.
3. Klupa T. Apoptoza-od teorii do praktyki. *Przegl Lek*, 1998; 55: 528-531.
4. Klinge O. Cytologic and histologic aspects of toxically induced liver reactions. *Current topics in pathology*. Ed.: Grundmann E., Kirsten W.H., Springer-Verlag Berlin, Heidelberg, New York V, 1973; 58: 91.
5. Sandritter W., Riede U.N. Morphology of liver cell necrosis. In: *Pathogenesis and mechanism of liver cell necrosis*. Ed.: Keppler D., MPT, 1974.
6. Chmielewski M., Linke K., Zabel M., Szuber L. Apoptosis in the liver. *Gastroent Pol*, 2003; 10: 453-462.
7. Kiliańska Z.M., Miskiewicz A. Kaspazy kregowcow; ich rola w przebiegu apoptozy. *Post Biol Kom*, 2003; 30: 129-150.
8. Sulejczak D. Apoptosis and methods of identification of the phenomenon. *Post Biol Kom*, 2000; 27: 527-568.
9. Domiński Z. Apoptoza: śmierć komórek w życiu organizmów zwierzęcych. *Kosmos*, 1999; 48: 385-396.
10. Fabbi M., Marimietri D., Martini S., Brancoloni C., Amoresano A., Scaloni A., Bargellesi A., Cosulich E. Tissue transglutaminase is a caspase substrate during apoptosis. Cleavage causes loss of transamidating function and is a biochemical marker of caspase 3 activation. *Cell Death Differ*, 1999; 6: 992-1001.
11. Izdebska M., Grzanka A., Ostrowski M. Rak pęcherza moczowego – molekularne podłoże genezy i leczenia. *Kosmos*, 2005; 54: 213-220.
12. Faubel S., Ljubanovic D., Reznikow L., Somerset H., Dinarello CA., Edelstein CL. Caspase-1-deficient mice are protected against cisplatin-induced apoptosis and acute tubular necrosis. *Kidney Int*, 2004; 66: 2202-2213.

## Correspondence address

Agnieszka Pedrycz  
Department of Histology and Embryology Medical University in  
Lublin, ul. Radziwiłłowska 11, 20-080 Lublin  
e-mail address: apw4@wp.pl; tel. 81 528 84 04