DOI: 10.12923/cipms-2026-0028 Curr. Issues Pharm. Med. Sci., Vol. 39, No. 3, Pages 189-193

Current Issues in Pharmacy and Medical Sciences
Formerly ANNALES UNIVERSITATIS MARIAE CURIE-SKLODOWSKA, SECTIO DDD, PHARMACIA

journal homepage: https://czasopisma.umlub.pl/curipms



Severe onset of newly diagnosed secondary immune thrombocytopenia in a 4-year-old patient as a complication of HHV-7 infection – A case report

Zuzanna Skiba[1], Aleksander Siwek[1], Julia Kowalczyk[1,2], Adrian Kowalczyk[1,2]*, Paulina Deleszkiewicz-Jóźwik[3], Monika Lejman[4], Joanna Zawitkowska[3]

[1] Student Scientific Society at the Department of Pediatric Hematology, Oncology, and Transplantology, Medical University of Lublin, Poland
[2] Doctoral School, Medical University of Lublin, Poland
[3] Department of Pediatric Hematology, Oncology, and Transplantology, Medical University of Lublin, Poland
[4] Independent Laboratory of Genetic Diagnostics, Medical University of Lublin, Poland

ARTICLE INFO

Received 25 November 2025
Accepted 06 March 2026

Keywords:
immune thrombocytopenia;
ITP;
human herpesvirus 7;
HHV-7.

ABSTRACT

Immune thrombocytopenia (ITP) is an acquired autoimmune disorder characterized by isolated thrombocytopenia. Viral infections are one of the most common triggers, particularly in children. However, the role of human herpesvirus 7 (HHV-7) in ITP pathogenesis has yet to be established. Here, we present the case of a previously healthy 4-year-old girl with severe hemorrhagic symptoms and a critically low platelet count of 2,000/μL. Additional laboratory tests confirmed an acute HHV-7 infection. Despite initial treatment with platelet transfusions and intravenous immunoglobulin, the patient's thrombocytopenia persisted, necessitating the introduction of glucocorticoids. The patient showed gradual clinical and hematological improvement, with complete resolution by day 19 of hospitalization. Other causes of secondary ITP, including malignancy and autoimmune diseases, were ruled out. This case suggests a possible association between HHV-7 infection and the onset of secondary ITP in children. The case underscores the importance of comprehensive viral diagnostics in pediatric patients with severe thrombocytopenia and emphasizes the need for further research on the role of HHV-7 in hematologic complications.

INTRODUCTION

Human herpesvirus 7 (HHV-7) is a DNA virus belonging to the Herpesviridae family and the Betaherpesvirinae subfamily. It was first isolated from the peripheral blood lymphocytes of a healthy patient in 1990. The virus demonstrates a marked tropism for cluster of differentiation 4 (CD4+) lymphocytes. Primary HHV-7 infection typically occurs during early childhood, most frequently between the ages of two and five, via droplet transmission and contact with saliva. Due to its ability to establish latency alongside ongoing viral replication in the salivary glands, HHV-7 can persist in the host for a lifetime. Consequently, anti-HHV-7 antibodies are detectable in over 90% of adults. HHV-7 is most often associated with sixth disease, post-transplant complications, Alzheimer's disease, and other neurological disorders [1,2]. It is important to note that viral infections are frequently identified as environmental triggers for immune thrombocytopenia (ITP) in pediatric patients [3]. Molecular mimicry between infectious components and platelet glycoproteins plays an important role in its development (*e.g.*, GP120 for human immunodeficiency virus (HIV) and GPIIb/IIIa for varicella zoster virus, cytomegalovirus (CMV), herpes simplex virus (HSV), and Epstein-Barr virus (EBV)). This similarity results in the production of antibodies against the virus that also bind to platelets. This leads to the destruction of platelets through phagocytosis by macrophages and possibly T-cell-mediated toxicity, resulting in thrombocytopenia (Figure 1) [4,5].

Molecular mimicry between pathogen-derived components and platelet glycoproteins is one of the mechanisms that can trigger secondary immune thrombocytopenia (ITP). Splenic macrophages recognize antibody-opsonized platelets via FcγR, which mediates phagocytosis and peripheral platelet destruction. This process can result in the presentation of platelet antigens to CD4+ T lymphocytes via MHC

* **Corresponding author**
e-mail: adriankowalczyk31@gmail.com

© 2026 Author(s). This is an open access article distributed under the Creative Commons Attribution-NonComercial-No Derivs licence (http://creativecommons.org/licenses/by-nc-nd/4.0/)

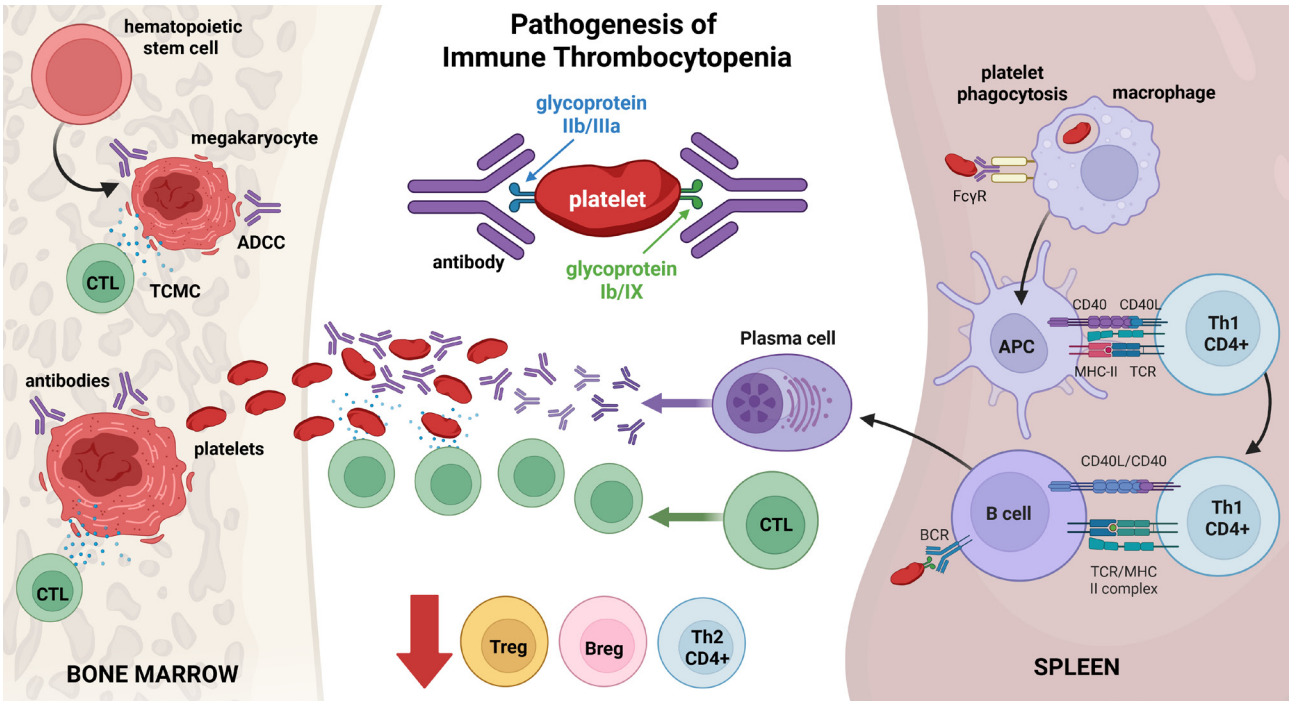

Figure 1. Pathophysiology of immune thrombocytopenia (Created with Biorender – accessed on 23.10.2025)

class II molecules. Activated, autoreactive CD4+ T lymphocytes participate in activating autoreactive CTLs and supporting B-cell differentiation into plasma cells that produce high-affinity, antiplatelet antibodies. These antibodies and CTLs can infiltrate the bone marrow, impairing megakaryocytopoiesis and reducing platelet production by megakaryocytes. Platelets are destroyed by TCMC and ADCC. The development and persistence of immune thrombocytopenia (ITP) is facilitated by immune-regulatory defects, including quantitative and functional defects of regulatory T cells (Treg) and regulatory B cells (Breg), as well as disturbances in the Th1/Th2 balance. ITP: immune thrombocytopenia; FcγR: Fc gamma receptor; CD4: cluster of differentiation 4; MHC: major histocompatibility complex; CTL: cytotoxic T lymphocyte; TCMC: T-cell-dependent cytotoxicity; ADCC: antibody-dependent cytotoxicity; Treg: regulatory T cells; Breg: regulatory B cells; Th: T helper cell; APC: antigen-presenting cell; CD40: cluster of differentiation 40; CD40L: CD40 ligand; TCR: T-cell receptor; BCR: B-cell receptor. Created with BioRender (accessed 10/23/2025). Unlike other members of the Herpesviridae family (*e.g.*, HSV, EBV, and HHV-6), HHV-7 has not yet been identified as a factor involved in the pathogenesis of ITP. Here, we present a pediatric patient with a severe, newly diagnosed case of secondary ITP that may have been induced by HHV-7 infection.

CASE PRESENTATION

A 4-year-old girl weighing 16.5 kg and measuring 114 cm tall (BMI: 12.7 kg/m²) was admitted to the Department of Pediatric Hematology, Oncology, and Transplantology in Lublin on Day 0 due to unplanned progressive signs of hemorrhagic diathesis, including petechiae, ecchymoses, and mucosal bleeding, which began one day prior to admission. The child had a history of a 2-3-week upper respiratory tract infection accompanied by a productive cough. Additionally, approximately one week prior to admission, all of the patient's family members exhibited symptoms of viral gastroenteritis. Upon admission, the patient was in generally good condition. She exhibited normal cardiovascular efficiency, appropriate physical activity, and mental responsiveness suitable for her age. She exhibited a mild fever of 37°C. A pediatric physical examination revealed extensive manifestations of hemorrhagic diathesis, including petechiae, ecchymoses, and hematomas on the torso and upper and lower limbs. Petechiae were also observed on the tongue and the mucous membranes lining the oral cavity (Figure 2).

At the time of admission, blood morphology examination described mild anemia (Hb – 11.1g/dl) and platelet count (PLT) at a critically low level of 2000/μL. Moreover, erythrocytes were found in a urinalysis. On Day 1 of hospitalization, the diagnostic procedures were expanded to virological and bacteriological blood tests, which detected presence of HHV-7 DNA. Other infectious factors such as CMV, EBV, HHV-6, HIV, noroviruses, *C. difficile*, pertussis and carbapenemase-producing bacteria were excluded. Also stool



Figure 2. Numerous petechiae, ecchymoses, hematomas on the skin of the face, torso and lower limbs of the patient. Petechiae on the tongue and the mucous membranes lining the oral cavity

tests were negative for the presence of *Helicobacter pylori*. Due to the severe symptoms of hemorrhagic diathesis, intravenous immunoglobulin (IVIG) administration at the total dose of 20 g was scheduled for the first day of hospitalization. Despite the introduced treatment, control morphology on Day 2 revealed an even lower PLT count of 1000/μL and hemoglobin at the level of 10.1 g/dl. Because of critical thrombocytopenia and persistent hematuria, the patient received platelet transfusion on Day 2. To prevent life-threatening hemorrhagic complications, further platelet transfusions were scheduled for Day 3 and Day 4, and an additional red blood cell transfusion was carried out on Day 4. After the transfusions, PLT reached the level of 4000/μL. A subsequently performed bone marrow aspiration biopsy confirmed the absence of a potential neoplastic process by excluding malignant infiltration or clonal proliferation. After excluding bone marrow proliferative disease, the patient was treated with intravenous methylprednisolone at the dose of 3 × 9 mg on Day 4. Due to thrombocytopenia of 1000/μL persisting from Day 4 for three consecutive days, another infusion of 20 g IVIG was scheduled. Over the next few days, platelet (PLT) levels steadily increased, reaching 75,000/μL on Day 11. Furthermore, a general urine examination on Day 12 revealed an absence of erythrocytes. From that point on, the patient's body gradually absorbed the changes, ultimately resolving completely by Day 16. Methylprednisolone therapy continued until day 18, after which the patient transitioned to oral prednisone at a dose of 14 mg, 10 mg, and 10 mg daily. Hospitalization was complicated by a rotavirus infection identified via stool tests on day 11. Symptomatic support included ondansetron for nausea, calcium supplementation, and intravenous fluids to correct hyponatremia. The patient was required to adhere to strict infection control protocols to prevent nosocomial spread, and resolution was confirmed by negative stool samples on Day 18. The patient was discharged on Day 20 in stable condition (PLT: 200,000/μL) with instructions to continue prednisone therapy. The patient was also scheduled for a follow-up appointment 16 days later. During the follow-up appointment, the blood count was normal (PLT: 187,000/μL), and prednisone therapy was discontinued. The patient's bleeding symptoms did not recur. The last follow-up occurred three months after the initial symptoms appeared (PLT: 311,000/μL). Figure 3 shows a diagram of the patient's disease course.

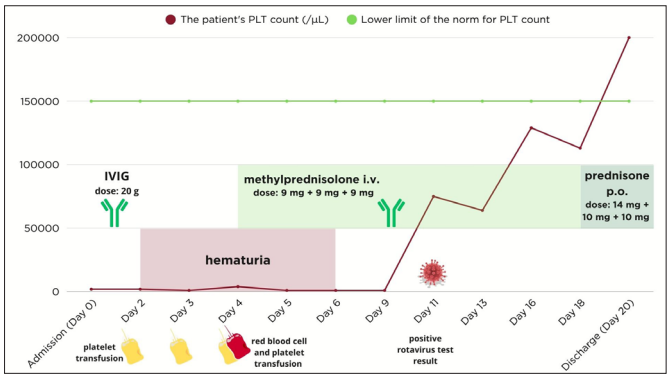

PLT – platelet count; IVIG – intravenous immunoglobulins, Created with Canva (accessed on 23.10.2025)

Figure 3. Medical history of patient

DISCUSSION

ITP is an acquired immune-mediated disorder that can be diagnosed when PLT is less than 100 × 10⁹/L [6]. From 2011 to 2016, the incidence of ITP diagnosis in the pediatric population in the United States was 8.8 per 100,000 person-years [7]. Primary ITP is diagnosed when no underlying cause of thrombocytopenia is found. In contrast, secondary ITP is associated with identifiable underlying conditions [8]. Numerous studies have documented the development of ITP following hematological malignancies, autoimmune disorders, primary immune deficiencies, or infections. Additionally, thrombocytopenia has been reported in rare cases following measles, mumps, rubella, and Coronavirus Disease 2019 (COVID-19) vaccinations [10]. Among various infectious agents, viruses are the most prevalent cause of secondary ITP. According to numerous studies, approximately 50-60% of ITP cases in the pediatric population are preceded by an upper respiratory infection [11].

Since the onset of the pandemic, SARS-CoV-2 has increasingly been recognized as a potential trigger for ITP. Donge *et al.* reported a case involving a five-and-a-half-year-old girl who was initially diagnosed with B-cell acute lymphoblastic leukemia (B-ALL). The patient had completed the induction and consolidation phases of chemotherapy and had been in the maintenance phase for five days when she developed symptoms of an active infection. A nasopharyngeal swab tested positive for SARS-CoV-2. Two weeks later, a laboratory evaluation revealed isolated thrombocytopenia. To distinguish between a possible B-ALL relapse and ITP secondary to SARS-CoV-2 infection, a bone marrow aspiration was performed. The findings showed a normocellular marrow with increased megakaryopoiesis and no blast cells, indicating ITP rather than leukemia relapse [12]. Other respiratory infections that contribute to the development of ITP include infectious mononucleosis, cytomegalovirus (CMV) infection, tuberculosis, and parvovirus B19 [13-15].

Additionally, numerous reports have documented cases of congenital rubella syndrome, hepatitis viruses, HIV, tuberculosis coinfection, and West Nile virus as potential etiological factors contributing to ITP in pediatric populations [16-19].

In our patient, a rotavirus infection occurred during hospitalization as well. However, the onset of thrombocytopenia and hemorrhagic symptoms occurred before the rotavirus infection was diagnosed, making it unlikely that the infection was the initial trigger. Although HHV-7 DNA was detected in the patient's peripheral blood, this finding does not distinguish between primary infection, reactivation, or latent persistence, all of which are common in the pediatric population. Therefore, the presence of HHV-7 may be incidental, and a definitive relationship cannot be confirmed. To our knowledge, no cases have been reported that link HHV-7 infection to the development of ITP, and further studies are required to explore this potential association.

In 1999, Sato *et al.* published a case report describing a patient with DiGeorge syndrome and HHV-7 infection who developed thrombocytopenia. However, this could be attributed to DiGeorge syndrome itself, as the condition is often associated with congenital bone

marrow abnormalities or a predisposition to autoimmune diseases [20].

Our patient was previously healthy, which underscores the exceptional nature of this case and the unusual presentation of the underlying condition. Furthermore, a study by Yoshikawa *et al.* demonstrated that HHV-6 contributes to bone marrow suppression, whereas HHV-7 does not [21]. These findings contradict the clinical presentation of our patient and underscore the need for further fundamental research on cell lines.

The current first-line treatment for ITP consists of intravenous immunoglobulin (IVIG) or glucocorticoids (GCS) [22]. According to treatment recommendations developed by the Polish Society of Pediatric Oncology and Hematology, the prednisone dosage is 4 mg/kg for three to four days or 1 to 2 mg/kg for two to three weeks, and the IVIG dosage is 0.8 to 1.0 g/kg for two days [23]. Response rates for IVIG use in ITP therapy are estimated to range from 60% to 80% [9,24]. In our patient, IVIG was administered at an individualized dose of 1.2 g/kg, slightly above the recommended dose of 1 g/kg, due to the patient's clinical condition: bleeding from the urinary tract and massive diathesis. Despite this, the treatment failed to achieve the intended outcome. Due to the failure of the first IVIG infusion and the patient's deteriorating condition, methylprednisolone was included in the treatment. A meta-analysis by Ren *et al.* evaluated the efficacy of different IVIG doses (≤1 g/kg vs. 2 g/kg) in ITP therapy in 1,989 pediatric patients and showed that the effective rate was similar in both groups regardless of the IVIG dose. The authors also evaluated the use of IVIG with and without steroids and found that IVIG therapy combined with intravenous glucocorticosteroids (GCS) was associated with a higher effective rate compared to IVIG monotherapy (91% vs. 86%) [25]. In our case, however, only synergistic therapy combining methylprednisolone with a second IVIG infusion led to improvement in the patient's clinical condition. This suggests that, for patients with severe ITP and extremely low platelet counts, IVIG infusion at higher doses is necessary to control symptoms.

A similar treatment approach was employed in a patient with DiGeorge syndrome who developed ITP, probably due to a cytomegalovirus (HHV-7) infection. In this case, therapy was initiated with IVIG, followed by the addition of GCS. Due to a lack of clinical improvement and life-threatening thrombocytopenia, a platelet concentrate transfusion was administered. Despite all therapeutic interventions, the patient died of an intracranial hemorrhage. In our case, multiple platelet transfusions were also used as an emergency intervention due to severe hematuria according to treatment recommendations developed by the Polish Society of Pediatric Oncology and Hematology [23].

Due to the unusually severe initial course of ITP in our patient, a bone marrow biopsy was performed before initiating steroid therapy to rule out leukemia as the cause of thrombocytopenia. This is consistent with treatment recommendations developed by the Polish Society of Pediatric Oncology and Hematology. However, the 2019 American Society of Hematology guidelines indicate that a bone marrow biopsy is unnecessary for children with typical ITP (grade 1B) and for patients with typical ITP prior to treatment with glucocorticosteroids (GCS) (grade 2C) [22]. However, the literature describes cases of concurrent ITP and T-cell malignancies in children, as well as cases in which chronic ITP refractory to therapy occurred before the development of lymphoma or leukemia [26]. Therefore, in cases of refractory ITP with an atypical course, it is important to exclude malignancy before using GCS.

If first-line drugs fail in ITP therapy, alternative therapeutic strategies should be considered. Currently, the second-line treatment consists of thrombopoietin receptor agonists, such as romiplostim and eltrombopag. In 2015, the FDA approved the use of 75 mg of maximum dose of eltrombopag for pediatric patients with chronic ITP who are one year of age or older and have demonstrated an inadequate response to glucocorticosteroids (GCS), intravenous immunoglobulin (IVIG), or splenectomy [27, 28]. In 2018, romiplostim, with a maximum dose of 10 μg/kg, was approved for use in children over one year of age with ITP that had persisted for over six months and had not responded to other treatments [29].

Other treatment methods include rituximab, a monoclonal antibody that targets CD20+ B cells and prevents the formation of autoreactive antibodies. Rituximab has proven to be an effective option for adult and pediatric ITP patients who are refractory to first-line treatment [30]. However, the use of rituximab has been associated with severe adverse effects, including an increased risk of infection due to the possibility of inducing long-term hypogammaglobulinemia, which requires a chronic supply of immunoglobulins in replacement doses [31]. Splenectomy could ultimately be taken into consideration [32]. According to Polish guidelines, a complete blood count should be monitored every seven days following any change in ITP medication. Once platelet levels reach an adequate level and remain stable, a complete blood count should be repeated every 30 days. After discontinuing treatment, blood tests may be reduced to the minimum necessary, e.g., every three to six months or immediately following an infection [23].

CONCLUSIONS

Although viral infections are well-known triggers of ITP, the role of HHV-7 is uncertain. Previous evidence has suggested that HHV-7 does not cause bone marrow suppression. The discrepancy between patients' symptoms and existing research highlights the complexity of viral infections affecting hematopoiesis. Further studies are needed to determine HHV-7's potential impact on platelet production. This case also emphasizes the importance of comprehensive viral diagnostics for pediatric patients with severe thrombocytopenia and the necessity of individualized treatment strategies.

ORCID iDs

Zuzanna Skiba https://orcid.org/0009-0002-8252-7385
Aleksander Siwek https://orcid.org/0009-0006-1855-3916
Julia Kowalczyk https://orcid.org/0009-0007-9765-376X
Adrian Kowalczyk https://orcid.org/0000-0003-3832-7941
Paulina Deleszkiewicz-Jóźwik https://orcid.org/0009-0009-8378-1626

Monika Lejman https://orcid.org/0000-0002-8760-0775
Joanna Zawitkowska https://orcid.org/0000-0001-7207-156X

REFERENCES

1. Verbeek R, Vandekerckhove L, Van Cleemput J. Update on human herpesvirus 7 pathogenesis and clinical aspects as a roadmap for future research. *J Virol*. 2024;98(6):e0043724. doi: 10.1128/jvi.00437-24.
2. Zhao M, Wang Y, Shen Y, Wei C, Zhang G, Sun L. A review of the roles of pathogens in Alzheimer's disease. *Front Neurosci*. 2024;18:1439055. doi: 10.3389/fnins.2024.1439055.
3. Thakur Y, Meshram RJ, Taksande A. Diagnosis and management of immune thrombocytopenia in paediatrics: a comprehensive review. *Cureus*. 2024;16(9):e69635. doi: 10.7759/cureus.69635.
4. Audia S, Mahévas M, Samson M, Godeau B, Bonnotte B. Pathogenesis of immune thrombocytopenia. *Autoimmun Rev*. 2017;16(6):620-632. doi: 10.1016/j.autrev.2017.04.012.
5. Martínez-Carballeira D, Bernardo Á, Caro A, Soto I, Gutiérrez L. Pathophysiology, clinical manifestations and diagnosis of immune thrombocytopenia: contextualization from a historical perspective. *Hematol Rep*. 2024;16(2):204-219. doi: 10.3390/hematolrep16020021.
6. Song JC, Liu SY, Zhu F, Wen AQ, Ma LH, Li WQ, Wu J, et al. Expert consensus on the diagnosis and treatment of thrombocytopenia in adult critical care patients in China. *Mil Med Res*. 2020;7(1):15. doi: 10.1186/s40779-020-00244-w.
7. Shaw J, Kilpatrick K, Eisen M, Tarantino M. The incidence and clinical burden of immune thrombocytopenia in pediatric patients in the United States. *Platelets*. 2020;31(3):307-314. doi: 10.1080/09537104.2019.1635687.
8. González-López TJ, Provan D, Bárez A, Bernardo-Gutiérrez A, Bernat S, Martínez-Carballeira D, et al. Primary and secondary immune thrombocytopenia (ITP): time for a rethink. *Blood Rev*. 2023;61:101112. doi: 10.1016/j.blre.2023.101112.
9. Mititelu A, Onisâi MC, Roşca A, Vlădăreanu AM. Current understanding of immune thrombocytopenia: a review of pathogenesis and treatment options. *Int J Mol Sci*. 2024;25(4):2163. doi: 10.3390/ijms25042163.
10. Gan G, Liu H, Liang Z, Zhang G, Liu X, Ma L. Vaccine-associated thrombocytopenia. *Thromb Res*. 2022;220:12-20. doi: 10.1016/j.thromres.2022.09.017.
11. Lim JH, Kim YK, Min SH, Kim SW, Lee YH, Lee JM. Epidemiology and viral etiology of pediatric immune thrombocytopenia through Korean public health data analysis. *J Clin Med*. 2021;10(7):1356. doi: 10.3390/jcm10071356.
12. Dongre A, Jameel PZ, Deshmukh M, Bhandarkar S. Immune thrombocytopenic purpura secondary to SARS-CoV-2 infection in a child with acute lymphoblastic leukaemia: a case report and review of literature. *BMJ Case Rep*. 2021;14(11):e245869. doi: 10.1136/bcr-2021-245869.
13. Abbasi F, Kaydani GA, Tahannezhad Z, Nakhaie M, Asnafi AA, Moradi M. Prevalence of cytomegalovirus and Epstein-Barr virus subclinical infection in patients with acute immune thrombocytopenic purpura. *Int J Hematol Oncol Stem Cell Res*. 2021;15(3):139-144. doi: 10.18502/ijhoscr.v15i3.6843.
14. Rama Krishna M, Gottam US, Mahendra N. Disseminated tuberculosis with severe immune thrombocytopenia. *Respir Med Case Rep*. 2019;27:100812. doi: 10.1016/j.rmcr.2019.02.013.
15. Algwaiz G, Alharbi A, Alsehaim K, Alahmari A, El Fakih R, Aljurf M. Hematologic manifestations of parvovirus B19 infection. *Hematol Oncol Stem Cell Ther*. 2023;16(4):316-322. doi: 10.56875/2589-0646.1031.
16. Kumar J, Sundaram V, Gupta K, Bhatia A, Kaur G, Dutta S. Congenital rubella syndrome as a possible cause for persistent thrombocytopenia in early infancy. *Autopsy Case Rep*. 2022;12:e2021386. doi: 10.4322/acr.2021.386.
17. Huang CE, Chang JJ, Wu YY, Huang SH, Chen WM, Hsu CC, et al. Different impacts of risk factors associated with thrombocytopenia in hepatitis B and C virus infection. *Biomed J*. 2022;45(5):788-797. doi: 10.1016/j.bj.2021.09.001.
18. Sandhya AS, Prajapat B. Thrombocytopenia in HIV patients coinfected with tuberculosis. *J Family Med Prim Care*. 2017;6(4):859-861. doi: 10.4103/jfmpc.jfmpc_250_17.
19. Onisâi M, Vlădăreanu AM, Iordan I, Bumbea H, Găman M, Ciufu C, et al. Primary, secondary or less frequent causes of immune thrombocytopenia: a case report. *Exp Ther Med*. 2021;22(4):1096. doi: 10.3892/etm.2021.10530.
20. Sato A, Nakagawa M, Nishizawa K, Narita T, Nishikawa R, Yamada A, et al. Thrombocytopenia after HHV-7 infection in DiGeorge syndrome. *J Pediatr Hematol Oncol*. 1999;21(2):171-172. doi: 10.1097/00043426-199903000-00018.
21. Yoshikawa T, Morooka M, Suga S, Niinomi Y, Kaneko T, Shinoda K, et al. Thrombocytopenia induced by primary HHV-6 infection. *Acta Paediatr Jpn*. 1998;40(3):278-281. doi: 10.1111/j.1442-200X.1998.tb01928.x.
22. Neunert C, Terrell DR, Arnold DM, Buchanan G, Cines DB, Cooper N, et al. American Society of Hematology 2019 guidelines for immune thrombocytopenia. *Blood Adv*. 2019;3(23):3829-3866. doi: 10.1182/bloodadvances.2019000966.
23. Łaguna P, Styczyński J, Kołtan S, Richert-Przygońska M, Karwacki M, Badowska W, et al. Pierwotna małopłytkowość immunologiczna – zalecenia postępowania. *Hematol Edu*. 2024;4(1-2):18-30. doi: 10.5603/hemedu.101676.
24. Cheng CN, Yang YN, Yeh YH, Chen LW, Chen JS, Lin YC. Predictors of remission in severe childhood immune thrombocytopenia. *Diagnostics*. 2023;13(3):341. doi: 10.3390/diagnostics13030341.
25. Ren X, Zhang M, Zhang X, Zhao P, Zhai W. Low-dose vs high-dose IVIG in newly diagnosed childhood ITP: systematic review. *BMC Pediatr*. 2024;24(1):199. doi: 10.1186/s12887-024-04677-3.
26. Denu RA, Matson DR, Davis MJ, Tedford NJ, Brichta CE, Diamond CA, Hoover-Regan ML. Association of ITP and T-lymphoblastic lymphoma in a pediatric patient. *Case Rep Hematol*. 2019;2019:1425151. doi: 10.1155/2019/1425151.
27. Winer ES, Safran H, Karaszewska B, Bauer S, Khan D, Doerfel S, et al. Eltrombopag for thrombocytopenia in patients with solid tumors receiving gemcitabine: phase 2 trial. *Int J Hematol*. 2017;106(6):765-776. doi: 10.1007/s12185-017-2319-9.
28. Russo G, Parodi E, Farruggia P, Notarangelo LD, Perrotta S, Casale M, et al. Acute ITP in children: recommendations from Italian Association of Pediatric Hematology and Oncology. *Blood Transfus*. 2024;22(3):253-265. doi: 10.2450/BloodTransfus.501.
29. Neunert CE, Rose MJ. Romiplostim in pediatric immune thrombocytopenia: development and practice. *Blood Adv*. 2019;3(12):1907-1915. doi: 10.1182/bloodadvances.2019000279.
30. Harris EM, Hillier K, Al-Samkari H, Berbert L, Grace RF. Response to rituximab in children and adults with ITP. *Res Pract Thromb Haemost*. 2021;5(6):e12587. doi: 10.1002/rth2.12587.
31. Lucchini E, Zaja F, Bussel J. Rituximab in immune thrombocytopenia: role in 2019. *Haematologica*. 2019;104(6):1124-1135. doi: 10.3324/haematol.2019.218883.
32. Vianelli N, Auteri G, Buccisano F, Carrai V, Baldacci E, Clissa C, et al. Refractory primary immune thrombocytopenia: challenges and perspectives. *Ann Hematol*. 2022;101(5):963-978. doi: 10.1007/s00277-022-04786-y.