DOI: 10.12923/cipms-2026-0025 Curr. Issues Pharm. Med. Sci., Vol. 39, No. 3, Pages 165-173

Current Issues in Pharmacy and Medical Sciences
Formerly ANNALES UNIVERSITATIS MARIAE CURIE-SKLODOWSKA, SECTIO DDD, PHARMACIA

journal homepage: https://czasopisma.umlub.pl/curipms

Histopathological study of the effects of *Decalobanthus mammosus* extract on liver necrosis in a tuberculosis mouse model

Rachmaniyah Rachmaniyah[1,2*], Win Darmanto[1,3], Dwi Winarni[1], Khambali Khambali[2], Fitri Rokhmalia[2]

[1] Department of Science and Technology, Faculty of Science and Technology, Universitas Airlangga, Surabaya, Indonesia
[2] Department of Environmental Health, Poltekkes Kemenkes Surabaya, Surabaya, Indonesia
[3] Instutute of Science, Technology and Health; ICME Jombang, Indonesia

ARTICLE INFO

Received 03 June 2026
Accepted 15 September 2026

Keywords:
Decalobanthus mammosus;
tuberculosis;
liver necrosis;
histopathology;
hepatoprotective.

ABSTRACT

Tuberculosis (TB) remains a global health problem, and hepatotoxicity associated with anti-TB therapy may complicate treatment. This study aimed to evaluate the effects of *Decalobanthus mammosus* tuber extract on liver histopathology in a *Mycobacterium tuberculosis*-infected mouse model. A post-test-only control group design was used involving 30 male Swiss albino mice allocated to five groups (n = 6 per group): a negative control group (K−; healthy, uninfected mice), an infected control group (K+; *M. tuberculosis*-infected mice without extract), and three treatment groups receiving *D. mammosus* extract at 200 mg/kg BW (P1), 400 mg/kg BW (P2), or 800 mg/kg BW (P3). Infection was induced intratracheally, followed by oral isoniazid therapy. Liver injury was assessed based on the mean number of necrotic cells across five microscopic fields per mouse and the ordinal Manja Roenigk score. The revised analysis treated the individual mouse as the experimental unit, used the Kruskal-Wallis test with Dunn's post hoc test for the ordinal score, and applied negative binomial regression to necrotic-cell counts. The observed mean necrotic-cell counts were 1.4 ± 0.2 in K−, 8.7 ± 0.3 in K+, 1.2 ± 0.1 in P1, 6.4 ± 0.9 in P2, and 13.5 ± 1.2 in P3. Histopathological findings showed relatively preserved hepatic architecture in P1 and more extensive injury in P3. These findings indicate a non-linear tissue response to *D. mammosus* extract; however, inferential *p*-values and effect estimates should be inserted after reanalysis of the individual-mouse data using the specified statistical models.

INTRODUCTION

Tuberculosis (TB) remains a major global public health problem despite advances in diagnosis and treatment, making efforts to reduce the burden of this disease a priority for international health [1]. Based on the latest disease burden analyses, millions of new TB cases are still estimated to occur each year, and TB mortality remains high, indicating that the challenges of TB control are complex and ongoing [2]. Particularly in high-burden countries, including Indonesia, TB prevention and treatment efforts face structural and biological barriers that slow the decline in disease incidence [2]. Important clinical challenges include the emergence of drug-resistant tuberculosis and adverse effects associated with anti-TB drugs, which together may reduce treatment success and highlight the need for additional safe and effective therapeutic strategies [2].

In addition to its common pulmonary manifestations, *Mycobacterium tuberculosis* can disseminate to other organs and cause extrapulmonary tuberculosis. Among the organs that can be affected, the liver is important both as a potential site of infection and as an organ susceptible to drug-induced toxicity [2]. Hepatic tuberculosis (HTB) may show characteristic granulomatous histopathological features with caseous necrosis, and diagnosis often requires histopathological examination because clinical manifestations and imaging findings may be nonspecific [2]. In addition, first-line anti-TB drugs such as isoniazid and rifampicin are known to cause varying degrees of hepatotoxicity, ranging from mild elevations in liver enzymes to significant

*** Corresponding author**
e-mail: windarmanto@fst.unair.ac.id; rachmaniyah.keslingsby@gmail.com

© 2026 Author(s). This is an open access article distributed under the Creative Commons Attribution-NonComercial-No Derivs licence (http://creativecommons.org/licenses/by/4.0/)

hepatocellular necrosis. Therefore, the management of patients with TB must consider the risk of liver injury caused by both infection and pharmacological treatment [3]. The mechanisms underlying anti-TB drug-induced hepatotoxicity involve reactive metabolites, oxidative stress, and activation of apoptotic or necroptotic pathways in hepatocytes; thus, the combined effects of mycobacterial infection and drug exposure may exacerbate liver tissue damage [4].

From an immunopathological perspective, liver macrophages (Kupffer cells) play a key role in the response to mycobacterial infection because they represent an important first line of defense capable of recognizing and phagocytosing pathogens and initiating inflammatory and intracellular antimicrobial responses [5]. Experimental studies indicate that Kupffer cells can limit the growth of *M. tuberculosis* through activation of autophagy pathways and regulation of intracellular metabolites. However, excessive immune activation may lead to increased production of pro-inflammatory cytokines and reactive oxygen species, thereby promoting hepatocyte injury [5]. The role of pro-inflammatory cytokines such as TNF-α and IL-1 in the pathogenesis of liver injury associated with infection and drug-induced toxicity has been documented, making the regulation of these cytokines an important indicator of the balance between protective immune responses and tissue pathology [6]. Furthermore, recent molecular findings have linked oxidative stress and programmed cell death pathways, including ferroptosis, to tissue injury during *M. tuberculosis* infection, providing a mechanistic basis for the role of lipid peroxidation and impaired intracellular antioxidant defenses in accelerating necrotic damage in affected organs [7].

In the context of adjuvant therapy, natural products and plant extracts have gained attention as potential immunomodulatory and hepatoprotective agents because of their bioactive compounds, including flavonoids, saponins, and polyphenols, which exhibit antioxidant and anti-inflammatory activities [8]. A comprehensive review of flavonoids has shown that this class of compounds can suppress oxidative stress, regulate cellular signaling pathways related to apoptosis and inflammation, and exert protective effects in various experimental models of liver injury [9]. In addition, methodological studies on flavonoid extraction and isolation emphasize that appropriate extraction techniques can improve yield and pharmacological activity, making extract preparation an important aspect of preclinical research on hepatoprotective effects [10].

Among the plants used in traditional medicine in Southeast Asia, members of the Convolvulaceae family, particularly species formerly classified within the genus *Merremia* and locally known as bidara upas, including *Decalobanthus mammosus* (syn. *Merremia mammosa*), have been reported to contain various pharmacologically active secondary metabolites [11]. *Decalobanthus mammosus* (Lour.) A.R. Simões & Staples (family Convolvulaceae) is a perennial climbing plant characterized by large tuberous roots, cordate leaves, and funnel-shaped flowers. The tuber is the most commonly used medicinal part and has traditionally been used for its anti-inflammatory and wound-healing properties. This species is distributed throughout Southeast Asia, particularly in Indonesia, Malaysia, Thailand, and the Philippines, where it grows in tropical and subtropical climates. Because of its bioactive secondary metabolites, *D. mammosus* has gained increasing attention as a potential source of hepatoprotective and immunomodulatory agents.

Scientific reviews of species within the former genus *Merremia* have documented the presence of flavonoids, tannins, saponins, terpenoids, and resin glycosides with potential antioxidant, anti-inflammatory, and antimicrobial activities, making these plants rational candidates for further therapeutic investigation [11]. Studies of metabolite and chemical profiles in *Merremia* tuber species have identified compounds associated with biological activities relevant to immune responses and oxidative stress; thus, these phytochemical findings support the hypothesis that extracts from these plants may modulate tissue damage under infectious conditions [12]. Several preclinical studies investigating the pharmacological properties of *Merremia* extracts have demonstrated wound-healing effects, antioxidant activity, and in silico activity against viral and bacterial targets, although controlled studies evaluating their effects in systemic disease models, particularly tuberculosis, remain limited [12,13].

Methodologically, preclinical studies examining the hepatoprotective effects of natural substances generally use quantitative and qualitative histopathological assessments to evaluate changes in hepatocyte morphology, the degree of necrosis, and tissue inflammatory markers, making histopathological examination an important benchmark for testing hypotheses related to liver tissue protection [14]. At the same time, studies evaluating the anti-TB and immunomodulatory effects of plants emphasize the importance of the relationship between dose, immune response phenotype, and potential toxic effects on target organs; therefore, determination of a safe and effective dose range should be accompanied by careful histopathological evaluation [8]. Although preliminary evidence indicates the pharmacological potential of the genus *Merremia*, adequate data on the specific effects of *Decalobanthus mammosus* (syn. *Merremia mammosa*) extract on liver histopathology in a *Mycobacterium tuberculosis* infection model remain limited, particularly with regard to necrotic-cell counts, histopathological scores, and dose-response relationships in the context of anti-TB therapy [11,12].

Although extensive research has been conducted on tuberculosis and the hepatotoxicity of anti-TB drugs, scientific evidence on adjuvant strategies capable of protecting the liver remains limited. Previous studies on the genus *Merremia* and the species *D. mammosus* have primarily focused on phytochemical characteristics, antioxidant activity, or wound-healing effects, without directly evaluating their effects on liver injury caused by *M. tuberculosis* infection. This gap has resulted in limited knowledge regarding the potential of this plant as a hepatoprotective agent in tuberculosis. Furthermore, there have been no studies specifically examining the dose-response relationship between *D. mammosus* extract and histopathological changes in the liver, particularly in the context of hepatocyte necrosis and granuloma formation associated with infection.

Based on this knowledge gap, this study aims to histopathologically evaluate the effects of *D. mammosus* extract on liver necrosis in a tuberculosis mouse model. This study

is expected to provide new insights into the potential of the extract as a hepatoprotective adjuvant agent by reducing liver tissue damage, suppressing excessive inflammation, and improving the local immune response. Thus, the results of this study will not only enrich the scientific evidence related to medicinal plant-based complementary therapies but also open up opportunities for the development of safer natural adjuvant candidates to support the success of tuberculosis treatment in the future.

METHODS

Research design

This study was a laboratory-based experimental study using a post-test-only control group design to evaluate the effect of *Decalobanthus mammosus* extract on histopathological changes in the liver of mice with induced *Mycobacterium tuberculosis* infection. The study was conducted under controlled laboratory conditions to minimize the influence of external factors on the results. The experimental animals were allocated to control and treatment groups, and histopathological examination of the liver was performed after completion of the entire treatment regimen. The study design was used to compare liver tissue conditions among healthy mice, infected mice that did not receive the extract, and infected mice administered *D. mammosus* extract at three dose levels.

Experimental animals and housing conditions

The study was conducted at the Animal Research Laboratory, Faculty of Science and Technology, Universitas Airlangga, Surabaya, Indonesia, between March and July 2024. The experimental animals were 8-10-week-old male Swiss albino mice (*Mus musculus*) weighing 20-25 g. A total of 30 mice were used and allocated into five groups, each comprising six mice.

The mice were housed at a temperature of 22-25 °C and a relative humidity of 50-60%, under a 12-h light/12-h dark cycle. During the housing period, the mice were provided with standard feed and had free access to drinking water. Before treatment began, all mice underwent a 7-day acclimatization period. The health status of the animals was monitored throughout the study period in accordance with the standard animal care procedures in force at the research facility.

Ethical approval

All procedures involving animals were conducted in accordance with the principles of animal research ethics and were approved by the Poltekkes Kemenkes Animal Research Ethics Committee in Surabaya (approval no. EA.2197/KEPK-Poltekkes_Sby/V/2024) and by the Animal Research Ethics Committee of Airlangga University in Surabaya, Indonesia (approval no.: KEPK-009; approved on February 12, 2024).

The research procedures were conducted with due regard for animal welfare and with the aim of minimizing pain and suffering throughout the study.

Euthanasia was performed by intramuscular administration of Ket-A-100 (ketamine, 100 mg/kg body weight) and Intercemie (xylazine, 10 mg/kg body weight) to ensure deep anesthesia and minimize the animals' suffering.

MATERIALS AND EQUIPMENT

The main materials used in this study were fresh tubers of *D. mammosus*, 70% ethanol, distilled water, 10% neutral buffered formalin, paraffin, hematoxylin and eosin (H&E) stain, and anesthetics consisting of ketamine and xylazine. Isoniazid was used as anti-tuberculosis therapy in accordance with the study protocol.

To meet the requirements for research reproducibility, the manufacturer and location of each main material should be specified in the manuscript. Ket-A-100, containing 100 mg/mL ketamine, and Intercemie, containing 20 mg/mL xylazine hydrochloride, were used for anesthesia and euthanasia procedures as specified in the research protocol. The equipment used included a drying oven or other drying apparatus, an analytical balance, a rotary evaporator, a water bath, a microtome, microscope slides, and a light microscope.

Preparation of *Decalobanthus mammosus* extract

Fresh tubers of *D. mammosus* were collected from Malang Regency, East Java, Indonesia, in April 2024. Plant identification and authentication were performed at the Biology Laboratory of Universitas Airlangga, Surabaya, Indonesia, and a voucher specimen numbered DM-UA-2024 was retained as a reference.

The collected tubers were washed to remove dirt, sliced, and dried at room temperature for 7 days until a constant weight was achieved. The dried material was subsequently ground into powder. The tuber powder was extracted with 70% ethanol by maceration for 72 h with periodic stirring. The extract filtrate was then concentrated using a rotary evaporator at 40-50 °C and subsequently dried in a water bath at 45°C until a solvent-free concentrated extract was obtained. The extract was not processed into powder and was stored as a thick concentrate at 4 °C until use. The extraction procedure was standardized with respect to solvent composition, extraction duration, and temperature to ensure consistency.

Phytochemical profile of the extract

The phytochemical profile of *D. mammosus* used in this study was based on previous reports indicating the presence of secondary metabolites, including flavonoids, saponins, tannins, terpenoids, and resin glycosides, in extracts of the plant tubers. Previous metabolomic studies have also reported the presence of flavonoid derivatives and resin glycosides in the tubers of *Merremia mammosa*, which is taxonomically related to *D. mammosus*.

This study did not quantify the individual concentrations of these compounds. Therefore, phytochemical content was not included as a quantitative variable in the statistical analysis. Standardization of the extract in this study was based on consistency in the plant material, solvent composition, maceration duration, evaporation temperature, and storage conditions.

Induction of *Mycobacterium tuberculosis* infection

After completion of the acclimatization period, mice assigned to the infection groups were infected with *Mycobacterium tuberculosis* via the intratracheal route. The intratracheal infection model was used to induce infection and enable evaluation of subsequent changes in liver tissue.

The *M. tuberculosis* inoculum was administered at a concentration of 10^8 CFU/mL, based on the protocol or preliminary studies used in this research. Following infection induction, the mice were monitored throughout the study period to ensure maintenance of the experimental conditions. Four weeks after infection induction, the mice received oral isoniazid therapy at a dose of 25 mg/kg body weight in accordance with the study protocol.

Group allocation and treatment administration

Following induction of infection and administration of isoniazid therapy in accordance with the study protocol, the mice were randomly allocated into five groups, each comprising six mice. Group K− served as the negative control and consisted of healthy mice without *M. tuberculosis* infection that did not receive the extract. Group K+ served as the positive control and consisted of mice with induced *M. tuberculosis* infection that did not receive *D. mammosus* extract. Groups P1, P2, and P3 were the treatment groups and received *D. mammosus* extract at doses of 200, 400, and 800 mg/kg body weight, respectively. The extract was administered daily for 5 weeks.

The extract was administered by oral gavage. Before administration, it was dissolved in distilled water to obtain a final concentration of 108 mg/mL. The treatment solution was prepared before each administration to ensure consistency of the delivered doses. Doses of 200, 400, and 800 mg/kg body weight were selected based on dose ranges used in previous studies and to account for potentially different biological responses at low, medium, and high doses.

Histopathological examination procedure

At the end of the treatment period, all mice were euthanized in accordance with the research ethics protocol. Anesthesia was administered intramuscularly using Ket-A-100, containing 100 mg/mL ketamine, and Intercemie, containing 20 mg/mL xylazine hydrochloride, at doses of 100 mg/kg and 10 mg/kg body weight, respectively. After death was confirmed by the absence of respiratory movements and cardiac activity, liver tissue was immediately collected for histopathological examination. The euthanasia and tissue collection procedures were performed with due consideration for minimizing pain and distress in the experimental animals.

Liver tissue was fixed in 10% neutral buffered formalin for 24 h and then processed using the paraffin-embedding method. The processed tissue was sectioned at a thickness of 5 μm using a microtome and mounted on glass slides. The sections were then stained with hematoxylin and eosin to visualize liver architecture and morphological changes in hepatocytes. The slides were examined under a light microscope at 400× magnification. Five microscopic fields were randomly selected from each slide to obtain a representative histopathological assessment of the liver tissue from each mouse.

Assessment of liver cell damage and necrosis

The degree of liver tissue damage was assessed using the Manja Roenigk histopathological scoring system. A score of 1 indicated normal tissue morphology without damage; a score of 2 indicated parenchymal degeneration; a score of 3 indicated hydropic degeneration; and a score of 4 indicated cell necrosis. In addition to histopathological scoring, the number of necrotic cells was quantified in five microscopic fields at 400× magnification.

To avoid pseudoreplication, individual mice were designated as the experimental units rather than individual microscopic fields. Observations from the five microscopic fields for each mouse were first summarized into a single value before statistical analysis. For necrotic-cell counts, the values from the five fields were averaged to obtain one representative count for each mouse. Thus, the five microscopic fields were treated as technical replicates within a single animal and were not considered independent observations. This approach ensured that the statistical analysis was based on six mice per group, consistent with the experimental units of the study.

Statistical analysis

The data were analyzed at the level of the experimental unit, *i.e.*, the individual mouse. The main study variables were the Manja Roenigk histopathological score, which is ordinal, and the number of necrotic cells, which is count data.

Because the Manja Roenigk score is measured on an ordinal scale from 1 to 4, these data were not analyzed using ANOVA. Differences in scores among groups were analyzed using the Kruskal-Wallis test. When a significant overall difference was detected, Dunn's test was used for post hoc comparisons with correction for multiple testing. Manja Roenigk scores are presented as the median and interquartile range (IQR). The level of statistical significance was set at $p < 0.05$. Post hoc p-values are reported after adjustment for multiple comparisons.

Necrotic-cell counts were analyzed as count data using negative binomial regression because count data may exhibit variance greater than the mean, indicating overdispersion. Model suitability was assessed based on the distribution of the data and the dispersion parameter. When overdispersion was present, negative binomial regression was used as the primary model. Prespecified comparisons focused on each extract dose group (P1, P2, and P3) versus the infected control group (K+), with adjustment for multiple comparisons. This approach was selected because the primary aim of the study was to determine whether each extract dose differed from the infected condition without extract administration rather than to perform all possible pairwise comparisons among groups.

Assumption testing was performed according to the type of data and the statistical methods used. Tests of normality and homogeneity of variance were not used as the basis for analysis of the Manja Roenigk scores because these scores are ordinal and were analyzed using nonparametric methods.

For necrotic-cell counts, the data distribution and potential overdispersion were evaluated before regression modeling. When parametric analysis of continuous data was required for additional analyses, residual normality and homogeneity of variance were assessed before applying parametric methods.

RESULTS

Histopathological changes in the liver

Histopathological examination revealed clear differences in liver damage among the experimental groups. The negative control group (K−) showed preserved liver architecture with predominantly normal hepatocytes and minimal cellular changes. In contrast, the infected control group (K+) exhibited hepatocyte swelling, inflammatory cell infiltration, sinusoidal congestion, and extensive cellular necrosis.

Mice receiving 200 mg/kg body weight of *D. mammosus* extract (P1) exhibited relatively preserved hepatic architecture, with mild cellular swelling and limited inflammatory infiltration. The group receiving 400 mg/kg body weight (P2) showed moderate hepatocellular degeneration and focal inflammatory infiltration, whereas the group receiving 800 mg/kg body weight (P3) showed more extensive changes, including sinusoidal congestion, prominent inflammatory infiltration, hepatocyte swelling, and widespread necrotic changes.

Overall, the histopathological findings indicate a nonlinear response to *D. mammosus* extract. The lowest dose was associated with relatively preserved liver morphology, whereas the highest dose was associated with more severe hepatic changes. These qualitative findings are consistent with the quantitative assessment of necrotic-cell counts and the Manja Roenigk histopathological scores presented in Table 1.

Table 1. Histopathological outcomes of the liver in tuberculosis-infected mice treated with *Decalobanthus mammosus* extract

Group	n	Necrotic cells/field, mean ± SD	Manja Roenigk score, median (IQR)
K−, healthy control	6	1.4 ± 0.2	1.0 (1.0-1.0)
K+, infected control	6	8.7 ± 0.3	4.0 (4.0-4.0)
P1, 200 mg/kg body weight	6	1.2 ± 0.1	1.0 (1.0-2.0)
P2, 400 mg/kg body weight	6	6.4 ± 0.9	3.5 (3.0-4.0)
P3, 800 mg/kg body weight	6	13.5 ± 1.2	4.0 (4.0-4.0)

Statistical analysis: The Kruskal-Wallis test was used for the Manja Roenigk score, and negative binomial regression was used for necrotic-cell counts
Abbreviations: IQR – interquartile range; SD – standard deviation

The mouse-level data showed a lower mean necrotic-cell count in P1 than in K+, whereas P2 remained closer to K+, and P3 showed the highest mean count. The Manja Roenigk scores similarly indicated normal or mildly altered tissue in K− and P1, intermediate injury in P2, and severe injury in K+ and P3.

Because the statistical analysis is being revised in response to the Statistical Editor's comments, inferential *p*-values and model estimates should be reported only after reanalysis of the individual-mouse data using the prespecified ordinal and count-data models.

Distribution of necrosis scores

The distribution of Manja Roenigk scores in each group is presented in Figure 1. Group P1 (200 mg/kg body weight) showed a predominance of scores 1-2, indicating mild degeneration, whereas P3 (800 mg/kg body weight) was dominated by score 4, indicating severe necrosis.

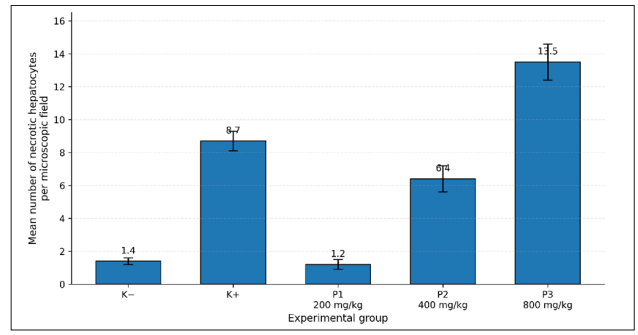

Figure 1. Distribution of necrotic hepatocyte counts across the experimental groups

The distribution of necrosis scores shown in Figure 1 further illustrates differences in the severity of tissue damage among the groups. Group K− showed a predominance of score 1, consistent with normal liver morphology, whereas group K+ was dominated by score 4, consistent with severe necrosis associated with infection. In the P1 group, the score distribution was concentrated at 1-2, indicating mild degeneration with most hepatocytes remaining intact. The P2 group showed a more heterogeneous distribution, with some mice showing improvement and others remaining at scores of 3-4, illustrating variability in the response to the medium dose. In the P3 group, the score distribution was almost entirely concentrated at level 4 and was more severe than that observed in K+, reinforcing the evidence that the high dose exacerbated tissue damage. Overall, this distribution pattern is consistent with the quantitative data and indicates a protective effect only at the low dose of the extract.

Histopathological description

The consistency of the findings was further confirmed by the histopathological images shown in Figure 2. In the K− group, hepatocytes appeared normal, with clear centrally located nuclei and homogeneous cytoplasm, indicating preserved cellular integrity. In contrast, the K+ group showed extensive necrosis with nuclear pyknosis and karyolysis, accompanied by disruption of hepatic lobular architecture.

A different pattern was observed in the P1 group, which received the low dose of the extract. Hepatocyte structure appeared better preserved, with minimal damage and most cells showing normal morphology, indicating a protective effect of the extract on liver tissue. In the P2 group, moderate degeneration was observed, with more apparent damage than in P1 but less severe changes than in K+. Meanwhile, the P3 group, which received the high dose, showed severe inflammation and extensive necrosis, with changes that were even more pronounced than those observed in K+.

These microscopic findings support the quantitative data and the distribution of histopathological scores, while also providing morphological evidence that *Decalobanthus*

mammosus extract may exert a hepatoprotective effect at low doses but may have the potential to induce toxicity at high doses.

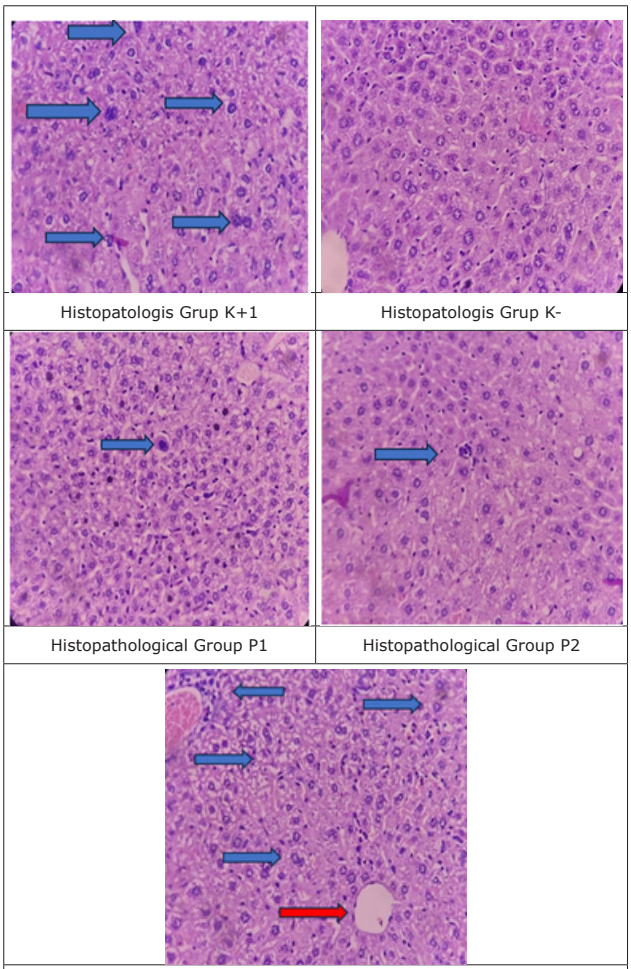

(A) K−: normal hepatocytes with intact nuclei and uniform cytoplasm
(B) K+: severe hepatocellular damage with ballooning degeneration, inflammatory infiltrates, sinusoidal congestion, and necrosis
(C) P1: preserved hepatic architecture with minimal degeneration
(D) P2: moderate degeneration with focal inflammatory infiltrates
(E) P3: extensive necrosis, severe inflammation, and sinusoidal congestion

Figure 2. Representative histopathological micrographs of mouse liver tissue (hematoxylin and eosin staining, 400× magnification; scale bar = 50 μm)

DISCUSSION

The results of this study indicate that administration of *Decalobanthus mammosus* extract produces a dose-dependent response in liver tissue, whereby low doses exert a protective effect on hepatocyte integrity, whereas high doses tend to increase signs of inflammation and necrosis. This dose-response pattern is consistent with observations that natural substances may exert therapeutic effects within a certain dose range but can have toxic effects when administered in excessive amounts [15].

These findings are clinically relevant because patients with tuberculosis are often exposed simultaneously to two sources of hepatic risk: infection with *Mycobacterium tuberculosis* and first-line anti-tuberculosis therapy with potentially hepatotoxic drugs such as isoniazid and rifampicin. Therefore, the identification of adjuvant agents that can protect the liver without reducing antimycobacterial efficacy is important [3,16].

The histopathological assessment performed in this study provides direct evidence of the cellular condition of the liver after treatment, as tissue examination remains a standard reference method for evaluating the degree of necroinflammation and patterns of hepatocyte injury in preclinical animal models [17].

The reduction in necrosis observed in the low-dose group is most likely related to the antioxidant and anti-inflammatory activities of secondary metabolites present in *Decalobanthus*/*Merremia*. Flavonoid and polyphenolic compounds commonly found in this group are known to suppress oxidative stress, reduce free radical production, and inhibit inflammatory signaling pathways, thereby contributing to hepatocellular protection in various experimental models [9]. Phytochemical support for this hypothesis is provided by metabolomic studies reporting the presence of flavonoids, saponins, and resin glycosides in *Merremia* tubers, which may help explain the antioxidant and immunomodulatory mechanisms observed in preclinical studies [12]. In addition, literature on natural product-based adjuvant therapy for tuberculosis indicates that several plant-derived compounds may enhance the intracellular response of macrophages to *M. tuberculosis* or reduce the adverse effects of anti-tuberculosis drugs through modulation of redox status. Therefore, the hypothesis that these extracts may act as host-directed adjuvants warrants further investigation [18,19].

Conversely, the increased necrosis observed in the high-dose group likely reflects two non-mutually exclusive mechanisms: a direct toxic effect of extract components on hepatocytes and excessive immune modulation that exacerbates tissue injury. This concept is consistent with reports that some herbal supplements may exhibit pro-oxidant or hepatotoxic effects at high concentrations or when particular constituents are present in excessive amounts [15,20]. This observation highlights the need to establish a safe therapeutic range through subchronic and chronic toxicity studies and phytochemical fractionation to identify both active compounds and constituents with the potential to cause adverse effects [12,21].

In the context of cellular mechanisms, the role of hepatic macrophages, or Kupffer cells, and the autophagy pathway deserves particular attention because these cells can limit mycobacterial growth but may also become a source of reactive oxygen species and inflammatory mediators when excessively activated. Thus, changes in Kupffer cell function may determine the balance between infection control and liver tissue injury [22]. Recent molecular evidence linking ferroptosis and oxidative stress to necrosis associated with *M. tuberculosis* infection also provides a relevant framework for interpreting the necrotic patterns observed in this study, as the antioxidant activity of the extract may suppress lipid peroxidation and preserve the activity of selenoprotein enzymes such as GPX4, thereby inhibiting ferroptosis [23,24]. Therefore, analysis of oxidative stress biomarkers and autophagy markers such as LC3 and Beclin-1 in tissue samples or isolated liver cells in future studies will be important to link the histological findings with the

molecular mechanisms underlying the protective or toxic effects of the extract [24,25].

The combination of mycobacterial infection and exposure to anti-tuberculosis drugs increases the complexity of interpretation because drugs such as isoniazid generate reactive metabolites that may exacerbate oxidative stress and hepatocellular injury. Therefore, adjuvant testing should consider possible pharmacodynamic and metabolic interactions between herbal extracts and standard anti-tuberculosis regimens [3]. In this context, a research design including a control group receiving anti-tuberculosis therapy alone and a group receiving a combination of anti-tuberculosis therapy and the extract is appropriate for assessing whether the extract exerts a synergistic protective effect or, conversely, increases drug-related toxicity. Similar recommendations have been reported in the literature regarding the evaluation of adjuvant agents in tuberculosis models [18,26].

Comparisons with other studies indicate that the use of plant extracts as hepatoprotective agents in infectious conditions is not a new concept; however, previous studies have often been limited to non-TB models or in vitro assessments. Therefore, in vivo evidence from tuberculosis models evaluating liver histopathological outcomes remains relatively scarce. The contribution of the present study to the literature is the provision of direct histological evidence in a pathophysiologically relevant model [19,28]. In addition, several studies on other plants have demonstrated a combination of antimycobacterial and hepatoprotective effects, reinforcing the concept that an appropriate formulation may provide dual benefits. However, the literature also indicates that in vitro findings do not always translate directly to animal or human models without appropriate dose and formulation optimization [28,29].

Although the LD_{50} of *Decalobanthus mammosus* extract has not been specifically reported, studies on related *Merremia* species indicate that the LD_{50} of ethanolic tuber extracts exceeds 2000 mg/kg body weight, suggesting relatively low acute toxicity. However, the present findings demonstrate that repeated administration at a high dose of 800 mg/kg body weight may induce hepatotoxic effects, highlighting the importance of dose optimization and subchronic toxicity assessment.

Mechanistically, the hepatoprotective effect observed at low doses of *D. mammosus* extract may plausibly be mediated through antioxidant, anti-inflammatory, and enzyme-modulating pathways. Flavonoids and polyphenols present in the extract are known to scavenge reactive oxygen species (ROS) and reduce lipid peroxidation, thereby protecting hepatocyte membranes from oxidative damage [9].

In addition, these compounds may inhibit pro-inflammatory signaling pathways such as NF-κB, leading to reduced production of cytokines, including TNF-α and IL-1β, which are key mediators of liver inflammation and necrosis [6,20]. Furthermore, modulation of endogenous antioxidant defenses, including superoxide dismutase (SOD), catalase (CAT), and glutathione (GSH), may contribute to maintaining intracellular redox balance [14,24].

Conversely, at higher doses, the extract may exert pro-oxidant effects or cause metabolic overload, leading to increased formation of reactive metabolites and hepatocellular stress, which may explain the exacerbation of necrosis observed in the P3 group. This dual effect supports the presence of a dose-dependent hormetic response, a phenomenon commonly observed in phytochemical-based therapies [30,31]

A major limitation of this study is the absence of biochemical liver function parameters, including serum alanine aminotransferase (ALT), aspartate aminotransferase (AST), alkaline phosphatase (ALP), and bilirubin levels. These biomarkers are widely recognized as standard indicators of hepatocellular injury and liver function, and their inclusion would have strengthened the interpretation of the hepatoprotective and hepatotoxic effects observed histologically.

However, this study specifically focused on histopathological endpoints as the primary outcomes, which are considered the gold standard for direct assessment of cellular- and tissue-level damage. Histological evaluation enables visualization of structural alterations such as necrosis, degeneration, and inflammation, which cannot be fully captured by biochemical assays alone. Therefore, although the absence of biochemical parameters limits functional interpretation, the consistency between quantitative necrosis assessment and morphological findings provides strong evidence of tissue-level effects. Future studies are strongly recommended to integrate both biochemical and histopathological analyses to provide a more comprehensive evaluation of liver injury.

Another limitation of this study is the absence of a reference hepatoprotective control drug, such as silymarin, which is commonly used as a benchmark in hepatoprotection studies. Inclusion of such a comparator would have allowed direct evaluation of the relative efficacy of *Decalobanthus mammosus* extract. However, the current study design was intended to specifically evaluate the dose-response relationship of the extract under conditions of tuberculosis-induced hepatic injury rather than its comparative efficacy. Despite this limitation, the significant reduction in necrosis observed in the low-dose group compared with the positive control provides preliminary evidence of hepatoprotective potential.

Based on these findings and limitations, several recommendations for further research can be made, including conducting phytochemical fractionation and characterization to identify and quantify active and potentially toxic compounds, performing subchronic toxicity studies across a wider dose range, and measuring a comprehensive panel of hepatic and oxidative stress biomarkers to link histological findings with functional liver parameters [12,21]. Furthermore, future studies should include analysis of autophagy markers (e.g., LC3 and Beclin-1), ferroptosis markers (e.g., GPX4 and lipid peroxides), and local inflammatory cytokine profiles to test the mechanistic hypothesis that tissue protection is mediated through redox modulation and intracellular clearance pathways in Kupffer cells and hepatocytes [24,25].

CONCLUSION

D. mammosus extract was associated with dose-related differences in liver histopathology in *M. tuberculosis*-infected mice. The 200 mg/kg body weight group showed relatively preserved hepatic architecture and a lower mouse-level necrotic-cell burden, whereas the 800 mg/kg body

weight group showed more extensive hepatic injury. These findings support a non-linear tissue response but do not, by themselves, establish clinical hepatoprotection or hepatotoxicity. Because the study did not include biochemical liver function markers or quantitative phytochemical characterization, the findings should be considered preliminary. Further studies should incorporate dose-ranging safety assessments, serum liver enzymes, oxidative stress biomarkers, quantitative phytochemical profiling, and molecular endpoints, together with prespecified statistical analyses based on the individual mouse as the experimental unit.

AVAILABILITY OF DATA AND MATERIALS

The data generated and analyzed during this study are available from the corresponding author upon reasonable request.

COMPETING INTERESTS

The authors declare no competing interests.

FUNDING

No funding was received.

ORCID iDs

Rachmaniyah Rachmaniyah https://orcid.org/0000-0001-6316-6874
Win Darmanto https://orcid.org/0000-0002-0488-403X
Dwi Winarni https://orcid.org/0000-0001-7688-0620
Khambali Khambali https://orcid.org/0000-0002-5085-0017
Fitri Rokhmalia https://orcid.org/0009-0005-8410-2964

REFERENCES

1. World Health Organization. *Global tuberculosis report 2024*. Geneva: World Health Organization; 2024.
2. Yang H, Ruan X, Li W, Xiong J, Zheng Y. Global, regional, and national burden of tuberculosis and attributable risk factors for 204 countries and territories, 1990-2021: a systematic analysis for the Global Burden of Diseases 2021 study. *BMC Public Health*. 2024;24:3111. doi:10.1186/s12889-024-20664-w.
3. Zhuang X, Li L, Liu T, Zhang R, Yang P, Wang X, et al. Mechanisms of isoniazid and rifampicin-induced liver injury and the effects of natural medicinal ingredients: a review. *Front Pharmacol*. 2022;13:1037814. doi:10.3389/fphar.2022.1037814.
4. Sankar J, Chauhan A, Singh R, Mahajan D. Isoniazid-historical development, metabolism associated toxicity and a perspective on its pharmacological improvement. *Front Pharmacol*. 2024;15:1441147. doi:10.3389/fphar.2024.1441147.
5. Kim JK, Park EJ, Jo EK. Itaconate, arginine, and gamma-aminobutyric acid: a host metabolite triad protective against mycobacterial infection. *Front Immunol*. 2022;13:832015. doi:10.3389/fimmu.2022.832015.
6. Tiegs G, Horst AK. TNF in the liver: targeting a central player in inflammation. *Semin Immunopathol*. 2022;44:445-59. doi:10.1007/s00281-022-00910-2.
7. Amaral EP, Namasivayam S, Queiroz ATL, Fukutani E, Hilligan KL, Aberman K, et al. BACH1 promotes tissue necrosis and *Mycobacterium tuberculosis* susceptibility. *Nat Microbiol*. 2024;9:120-35. doi:10.1038/s41564-023-01523-7.
8. Pandey B, Baral R, Kaundinnyayana A, Panta S. Promising hepatoprotective agents from the natural sources: a study of scientific evidence. *Egypt Liver J*. 2023;13. doi:10.1186/s43066-023-00248-w.
9. Gajender, Mazumder A, Sharma A, Azad MAK. A comprehensive review of the pharmacological importance of dietary flavonoids as hepatoprotective agents. *Evid Based Complement Alternat Med*. 2023;2023:4139117. doi:10.1155/2023/4139117.
10. Qin Y, Zhao B, Deng H, Zhang M, Qiao Y, Liu Q, et al. Isolation and quantification of the hepatoprotective flavonoids from *Scleromitron diffusum* (Willd.) R.J. Wang with bio-enzymatic method against NAFLD by UPLC-MS/MS. *Front Pharmacol*. 2022;13:890148. doi:10.3389/fphar.2022.890148.
11. Olatunji TL, Adetunji AE, Olisah C, Idris OA, Saliu OD, Siebert F. Research progression of the genus Merremia: a comprehensive review on the nutritional value, ethnomedicinal uses, phytochemistry, pharmacology, and toxicity. *Plants* (Basel). 2021;10(10):2070. doi:10.3390/plants10102070.
12. Purwitasari N, Agil M. Metabolite profiling of extract and fractions of bidara upas (*Merremia mammosa* (Lour.) Hallier F.) tuber using UPLC-QToF-MS/MS. *Biomed Pharmacol J*. 2022;15:2025-41.
13. Purwitasari N, Agil M, Siswodihardjo S, Nidom RV. Bidara Upas (*Merremia mammosa* Hall) antiviral activity against SARS-CoV-2. *J Med Chem Sci*. 2023;6:3149-58. doi:10.26655/JMCHEMSCI.2023.12.28.
14. Hossain KN, Islam MS, Rahman SH, Sarker S, Mondal M, Rahman MA, et al. *In vitro* antioxidant and in vivo hepatoprotective properties of Wissadula periplocifolia extract. *ACS Omega*. 2023;8:47001-11. doi:10.1021/acsomega.3c06614.
15. Woo SM, Davis WD, Aggarwal S, Clinton JW, Kiparizoska S, Lewis JH. Herbal and dietary supplement induced liver injury: highlights from the recent literature. *World J Hepatol*. 2021;13:1019-41. doi:10.4254/wjh.v13.i9.1019.
16. Oscanoa TJ, Vidal X, Luque J, Julca DI, Romero-Ortuno R. Hepatotoxicity induced by isoniazid in patients with latent tuberculosis infection: a meta-analysis. *Gastroenterol Hepatol Bed Bench*. 2023;16:448-57. doi:10.22037/ghfbb.v16i1.2685.
17. Tong X, Wang Q, Zhao X, Sun Y, Wu X, Yang L, et al. Histological assessment based on liver biopsy: the value and challenges in NASH drug development. *Acta Pharmacol Sin*. 2022;43:1200-9. doi:10.1038/s41401-022-00874-x.
18. Fatima S, Kumari A, Dwivedi VP. Advances in adjunct therapy against tuberculosis: deciphering the emerging role of phytochemicals. *MedComm* (2020). 2021;2:494-513. doi:10.1002/mco2.82.
19. Huang X, Lowrie DB, Fan XY, Hu Z. Natural products in anti-tuberculosis host-directed therapy. *Biomed Pharmacother*. 2024;171:116087. doi:10.1016/j.biopha.2023.116087.
20. Patel-Rodrigues PA, Cundra L, Alhaqqan D, Gildea DT, Woo SM, Lewis JH. Herbal- and dietary-supplement-induced liver injury: a review of the recent literature. *Livers*. 2024;4:94-118. doi:10.3390/livers4010008.
21. Dimitrov S, Slavchev I, Simeonova R, Mileva M, Pencheva T, Philipov S, et al. Evaluation of acute and sub-acute toxicity, oxidative stress and molecular docking of two nitrofuranyl amides as promising anti-tuberculosis agents. *Biomolecules*. 2023;13(8):1174. doi:10.3390/biom13081174.
22. Ahmad F, Rani A, Alam A, Zarin S, Pandey S, Singh H, et al. Macrophage: a cell with many faces and functions in tuberculosis. Front Immunol. 2022;13:747799. doi:10.3389/fimmu.2022.747799.
23. Qiang L, Zhang Y, Lei Z, Lu Z, Tan S, Ge P, et al. A mycobacterial effector promotes ferroptosis-dependent pathogenicity and dissemination. *Nat Commun*. 2023;14. doi:10.1038/s41467-023-37148-x.
24. Amaral EP, Foreman TW, Namasivayam S, Hilligan KL, Kauffman KD, Bomfim CCB, et al. GPX4 regulates cellular necrosis and host resistance in *Mycobacterium tuberculosis* infection. *J Exp Med*. 2022;219:e20220504. doi:10.1084/jem.20220504.
25. Silwal P, Paik S, Kim JK, Yoshimori T, Jo EK. Regulatory mechanisms of autophagy-targeted antimicrobial therapeutics against mycobacterial infection. *Front Cell Infect Microbiol*. 2021;11:633360. doi:10.3389/fcimb.2021.633360.
26. Cubillos-Angulo JM, Nogueira BMF, Arriaga MB, Barreto-Duarte B, Araújo-Pereira M, Fernandes CD, et al. Host-directed therapies in pulmonary tuberculosis: updates on anti-inflammatory drugs. *Front Med* (Lausanne). 2022;9:970408. doi:10.3389/fmed.2022.970408.
27. Gautam S, Qureshi KA, Pasha SBJ, Dhanasekaran S, Aspatwar A, Parkkila S, et al. Medicinal plants as therapeutic alternatives to combat *Mycobacterium tuberculosis*: a comprehensive review. *Antibiotics* (Basel). 2023;12(3):541. doi:10.3390/antibiotics12030541.

28. Balkrishna A, Joshi M, Kabdwal M, Tomer M, Lochab S, Varshney A. Robust anti-tubercular profile of *Solanum virginianum* extract in enhancing isoniazid bioavailability and curtailing stress tolerance in Mycobacterium smegmatis. *Front Microbiol*. 2024;15:1429027. doi:10.3389/fmicb.2024.1429027.
29. Raqib R, Sarker P. Repurposed drugs and plant-derived natural products as potential host-directed therapeutic candidates for tuberculosis. *Biomolecules*. 2024;14(12):1497. doi:10.3390/biom14121497.
30. Di Giosia P, Stamerra CA, Giorgini P, Jamialahmadi T, Butler AE, Sahebkar A. The role of nutrition in inflammaging. *Ageing Res Rev*. 2022;77:101596. doi:10.1016/j.arr.2022.101596.
31. Wijesinghe TP, Dharmasivam M, Dai CC, Richardson DR. Innovative therapies for neuroblastoma: the surprisingly potent role of iron chelation in up-regulating metastasis and tumor suppressors and down-regulating the key oncogene, N-myc. *Pharmacol Res*. 2021;173:105889. doi:10.1016/j.phrs.2021.105889.