

Current Issues in Pharmacy and Medical Sciences

Formerly ANNALES UNIVERSITATIS MARIAE CURIE-SKŁODOWSKA, SECTIO DDD, PHARMACIA

journal homepage: <http://www.curipms.umlub.pl/>



Development of herpetic infection associated with stroke and its correction with acyclovir

ALLA GUMENYUK¹, NATALIA MOTORNA¹, SVETLANA RYBALKO², SERGEY SAVOSKO¹,
LIUDMYLA SOKURENKO¹, DARIA STAROSYLA², YURI PORVA², YURI CHAIKOVSKY^{1*}

¹ Bogomolets National Medical University, T. Shevchenko boulevard 13, 01601, Kyiv, Ukraine

² Gromashevsky L.V. Institute of Epidemiology and Infection Diseases, NAMS of Ukraine, Amosova 5, 03038, Kyiv, Ukraine

ARTICLE INFO

Received 25 October 2016
Accepted 23 January 2017

Keywords:

HSV I,
Herpes Simplex Virus,
stroke,
acyclovir,
Vero cell culture.

ABSTRACT

Background: Herpes simplex virus (HSV) is prevalent in today's world population, and there is evidence of potential HSV reactivation in patients with immune deficiency induced by acute stroke. However, the data on the use of antivirals in the setting of stroke are scarce. The aim of this study was to evaluate the reactivation of HSV-1 in patients with stroke, using several methods, and to assess the efficacy of acyclovir in the treatment of experimental stroke. In the employed methodology, PCR and dot-ELISA were used to detect the occurrence of HSV-1 in patients with acute stroke. White mice were infected with HSV-1 and experimental stroke was simulated. The infected mice with stroke were subdivided into two groups: one of them received no treatment, while the other one was treated with acyclovir. The level of HSV-1 reactivation was determined by the methods used in human patients. The brain tissue of experimental animals was also subjected to morphological and morphometrical study. The results of such work reveal that, by the applied serological method, HSV-1 was found in all patients with stroke. Herein, the increased level of HSV-1 was seen in the brain tissue and blood in 100% of the experimental infected animals. However, the use of acyclovir suppressed reproduction of HSV-1. Hence, it can be concluded that clinical and laboratory studies have demonstrated the different sensitivity of Dot-Elisa and PCR, with the former being more sensitive. Moreover, the use of acyclovir in the experiment inhibited viral reproduction and further development of viral infection. Still, chemic lesions in the brain persisted.

INTRODUCTION

Cerebrovascular accidents are one of the leading contributors to morbidity and mortality [11]. The algorithm of first aid, treatment and rehabilitation of patients with stroke based on clinical observations and experimental studies is well described [1,7], yet, the infectious process, which can develop in the presence of immune deficiency in patients with acute stroke, has not received due attention. It has been demonstrated that Herpes simplex virus (HSV type I and II), prevalent in the general population, may cause meningitis and vasculitis in patients with stroke [9]. That is why reactivation of HSV in neurons, the budding of virions from the infected cells and subsequent cell death are a separate issue of disease pathogenesis. Moreover, the virus can be detected

only when reactivated, which is the result of the immune system being compromised [6].

In our previous study [4], we have shown that the experimental ischemic brain damage was a factor of the HSV-1 reactivation being characterized by a higher rate of neurodegenerative changes in the hippocampus, as compared to the neuroinfection or the impairment of cerebral circulation not related to infection. The aim of this study was to evaluate the reactivation of HSV-1 in patients with stroke, using several methods, and to assess the efficacy of an antiviral drug acyclovir in the treatment of experimental stroke.

MATERIALS AND METHODS

In this study, we attempted to simulate one of the most common clinical cases of complications in patients with impaired brain circulation, including hemorrhagic stroke. We tried to simulate in laboratory animals, the pathological

* Corresponding author

e-mail: yuchaiko@i.ua
phone: +38 (044) 454-49-89

process that by the specific features of the development and sequence of events (episodes of damage) were most similar to clinical conditions. This we felt was important for further pre-clinical study of the efficacy of antiviral drugs in animals with comorbidities, not just the primary viral infection. For the latter, experimental models are actively applied and accepted. Accordingly, the methodology of our research included the following steps:

1. Laboratory determination of the presence of HSV-1 in patients with stroke.
2. Simulating of local hemorrhagic stroke in animals with latent infection.
3. Evaluating the efficacy of antiviral drug acyclovir in the treatment of acute infection with HSV-1 after simulation of hemorrhagic stroke in animals.

To establish persistent herpes infection in patients with acute stroke, we first conducted laboratory determination of HSV-1 in the blood of 7 patients with acute stroke (3-7 days after the stroke episode, the acute period). PCR and dot-ELISA were then used to detect HSV-1 in the patients' sera, and to determine the infectious titer in Vero cell culture. HSV level in patients was determined in the clinical laboratory in the course of the standard complete blood cytology and biochemistry testing. The patients gave their written informed consent to using these data for analytical and statistical evaluation.

Our experiment was conducted on white mice weighing 18-20 g. The animals were subdivided into 3 groups (Tab. 1).

Table 1. The groups of animals

	Group	N of animals
1	Control, intact mice	10
2	HSV-1 with hemorrhagic stroke	37
3	HSV-1 with hemorrhagic stroke+acyclovir	48

In our experiment, we simulated experimental stroke and subsequent reactivation of HSV-1 according to the development and sequence of events (episodes of damage similar to clinical conditions). Doing such was important for further preclinical study of the efficacy of the tested antiviral drug in animals.

To infect the laboratory animals, we used the freeze-dried HSV type I VC strain. 0.03 ml of viral material, which equals to LD₅₀. This was inoculated into the brains of the mice. Initial symptoms of the infectious condition in the control were observed in 5-6 days after the infection, and reached their maximum by day 13-14, with the following subsidence of symptoms and recovery of animals. We assume that this is the time when HSV-I transfers into its latent form. This meningoencephalitis model is 100% reproducible and does not require any additional methods of control.

On day 30-40 after the regression of the viral infection signs (weakness, hypokinesia, decreased food and water requirements), a hemorrhagic stroke was simulated in the survivors. Cerebral hemorrhage in animals was simulated by inoculation of 0.15-0.2 ml of autologous blood into the right hemisphere (L = 1.5; H = 3.0; AP = 1.0) [8]. For this purpose, we predefined coordinates of input of cannula with blood, with help of an stereotactic atlas [2]. All hematoma were localized in the right internal capsule of the brain.

Animals of group 3 were subsequently treated with 50 mg/kg of acyclovir intraperitoneally once a day for 10 days. After 10 days following drug administration, they were euthanized with observance of all bioethical norms and rules of the „Regulations on the animal use in biomedical research”, „European Convention for the protection of vertebrate animals used for experimental and other scientific purposes”, „Guide for the Care and Use of Laboratory Animals”.

For histological examination, the murine brain was fixed in 10% formalin solution in 0.1 M phosphate buffer (pH 7.4), and dehydrated in ascending concentrations of ethanol and embedded in paraffin as per the standard procedure. The 6-8 µm thick paraffin slices were stained with H&En. The morphometric study included assessment of the changes in a number of damaged neurons in the frontal hippocampal sections. Herein, the microphotographs were taken with an Olympus BX 51 microscope. The morphometric analysis was performed using CarlZeiss (AxioVision SE64 Rel.4.9.1) software, magnification ×400. Statistica 6.0 software was employed for statistical processing of the obtained data using Student t-test.

At the time of the euthanasia of the laboratory animals, hippocampal CA1 sector samples were isolated for electron microscopy. Fragments were fixed in 2.5% solution of glutaraldehyde in phosphate buffer, with postfixation in 1% solution of osmium tetroxide. Dehydration was carried out in alcohols of ascending concentration (70%, 80%, 90%, 100%) and acetone. All biological samples were subsequently infiltrated and embedded in Araldite-Epon mixture. Ultrathin sections (60-70 nm) were contrasted with 2% solution of uranylacetate and lead citrate, studied and photographed under electron microscope (Tescan Mira 3 LMU (Czech Republic)) at magnification of 10-80 thousand.

PCR and dot-ELISA were used to confirm HSV-1 reproduction by detecting viral antigens in Vero cell culture. Vero cell culture was grown in sterile trays (“Nunc”). The infected trays were then incubated in culture medium (88% RPMI 1640 medium “Sigma”) with the addition of 12% of heat inactivated fetal calf serum (FCS) and antibiotics at 37°C with 5% of CO₂. Cytopathic activity (CPA) – syncytia formation – served as a marker of viral reproduction.

HSV-1 DNA in biological specimens was found by utilizing PCR with hybridization-fluorescent detection, using the set of reagents: “AmplifySensR HSV-1, II-FL”. A “DNA-sorb-AM” set of reagents was used for DNA extraction. DNA was extracted from each studied specimen in the presence of an internal control specimen (BKO-FL).

Dot-ELISA was performed on nitrocellulose filters. The filters with the applied specimens were dried and immersed in the solution containing 30 mg/ml BSA in 0.01 M Tris pH 7.5 – 0.15 M NaCl buffer, and incubated for two hours at 37°C. After the incubation in PAP (peroxidase-antiperoxidase complex), the filters were rinsed six times and immersed into the substrate for an enzyme to develop: 3.8 ml of DAB (diaminobenzidine tetrachloride) + 0.2 ml of 0.1% H₂O₂. The reaction was registered when the centers of the wells turned yellow.

To test the specificity of the response, we have set the following controls:

1. Control without protein A conjugate labeled with peroxidase.
2. Control of antigen without specific sera.
3. Control with normal rabbit serum.
4. The control sample without antigen.

RESULTS AND DISCUSSION

In our human test population, molecular biology techniques utilizing serum samples confirmed the presence of HSV-1. The dot-ELISA assay detected HSV-1 in 100% of samples, while the PCR gave negative results. Infectious herpes virus titer did not significantly differ in patients with three types of stroke: subarachnoid hemorrhage – 1,0-2,0 lg ID₅₀, ischemic stroke – 1,0-1,5 lg ID₅₀, parenchymal nontraumatic hemorrhage – 1,5 lg ID₅₀ (Tab. 2).

Table 2. HSV-1 in serum of patients with stroke (by ICD-10)

Clinical case	CPA of the infectious titer, lg ID ₅₀	Dot-Elisa	PCR
Hemorrhagic stroke (I.61)	1.5	positive	negative
Ischemic stroke (I.63)	1.5	positive	negative
Ischemic stroke (I.63)	1.0	positive	negative
Subarachnoid hemorrhage (I.60)	1.5	positive	negative
Subarachnoid hemorrhage (I.60)	1.5	positive	negative
Subarachnoid hemorrhage (I.60)	1.0	positive	negative
Subarachnoid hemorrhage (I.60)	2.0	positive	negative

HSV-type 1 was detected in all biological samples of group 2 laboratory animals (Tab. 3). In group 3, the rate of identification differed depending on the method of detection. While positive and negative reactions were found in the sera of animals, in tissue samples, HSV-1 was observed in all the cases.

Table 3. HSV-1 in serum and brain tissue of the infected animals

Group	CPA of infectious titer, blood/brain, lg ID ₅₀	Dot-Elisa, blood/brain	PCR, blood/brain
Control	0	0	0
HSV-1 with hemorrhagic stroke	2.0-4.0/2.0-4.0	positive/positive	positive/positive
HSV-1 with hemorrhagic stroke+acyclovir	0.0-1.0/1.0-2.0	positive/positive	negative/negative

In the histological examination of the hippocampus structural changes, our attention was focused on verifying the morphological manifestations of ischemic damage and neuronal cell death.

In experimental group 2, the pyramidal neurons of the CA1 hippocampal sector of the ipsilateral hemisphere were noted to be characterized by their development of cytoplasm edema and karyopnicosis (Fig. 1). Many neurons and gliocytes were also apoptotic (Tab. 4).

In experimental group 3, we observed a reduction of degree of the neurodystrophic process (Tab. 4). Morphometric analysis also showed a decrease in the number of neurons with signs of apoptosis and hydropic degeneration in the acyclovir group. We registered equally both marked apoptosis and necrosis of neurons. Furthermore, the total number of infected cells was statistically significantly lower, when

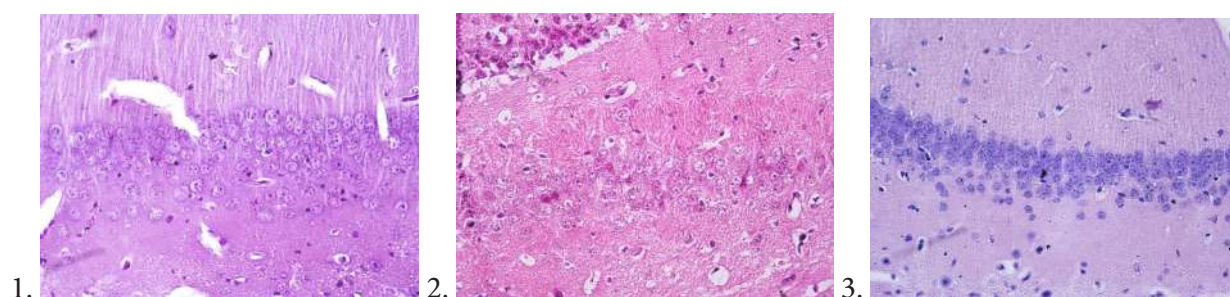


Figure 1. Histopathological changes. 1 – control group: intact pyramidal neurons (H&E: ×400); 2 – group 2: neurodegeneration in CA1 hippocampal sector (H&E: ×400); 3 – more undamaged neurons, inhibition of neurodegeneration (H&E: ×400).

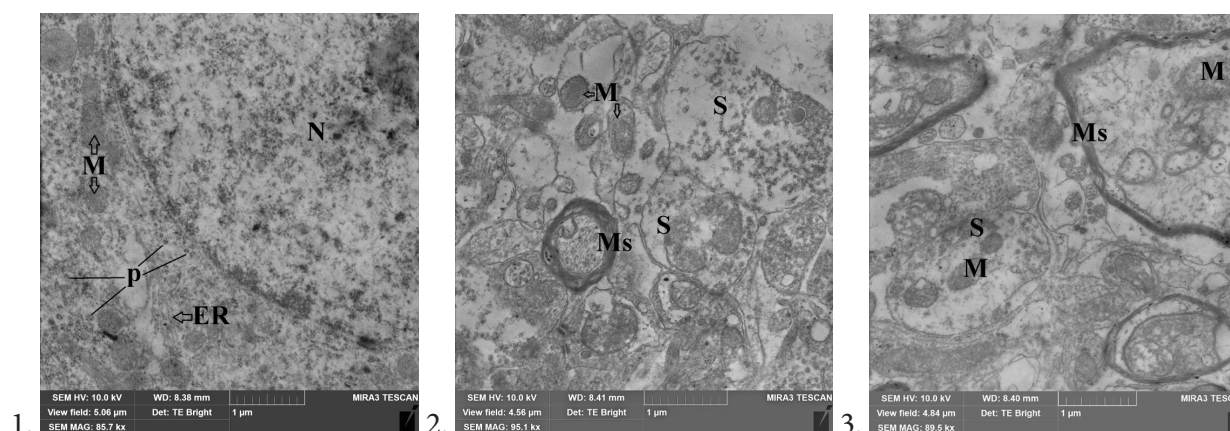


Figure 2. Electron microscopy changes in the hippocampus. 1 – Control group: intact nucleus, mitochondria and polysomes in neuron; 2 – group 2: destruction of synapses, nerve fibers and reduction of organelles in neurons; 3 – group 3: impairment of synapses, destruction of nerve fibers. ER – Endoplasmic reticulum, M – Mitochondria, Ms – Myelin sheath, N – Nucleus, p – Polysomes, S – Synapses

compared with the group which did not receive the antiviral drug (Tab. 4). However, electron microscopy revealed impairment of neurons and gliocytes, disorganization and destruction of synapses, and the loss of cytoskeletal elements in the nerve fibers in both groups of animals (Fig. 2). In addition, we registered the emergence of lamellar membranous bodies in the cytoplasm of some neurons and gliocytes, but we did not observe any clusters and conglomerates of the newly formed virions. Therefore, the use of molecular biology techniques in the detection of HSV-1 in both the clinical and experimental material we consider to be appropriate and necessary.

Table 4. Morphometric parameters of hippocampal CA1 neurons sector

Group	Quantity of damaged neurons, %		
	General quantity	With hydropic degeneration	With apoptosis
Control	5.6±0.1	2.2±1.7	3.0±0.4
HSV-1 with hemorrhagic stroke	62.0±4.2	29.4±2.2	32.5±4.3
HSV-1 with hemorrhagic stroke+acyclovir	28.7±0.7*	16.1±1.8*	12.5±1.4*

* – statistically significant differences compared with group 2 – HSV-1 with hemorrhagic stroke ($p < 0,05$).

The research results allow us to conclude that hemorrhagic stroke is a pathogenic factor of HSV-1 reactivation. Still, the latter has yet to be completely studied in terms of diagnosis and therapy, and the results of laboratory detection of herpes infection in biological samples (blood, CSF) of healthy individuals and patients with stroke remain inadequately assessed. It is known, however, that about 90% of the population harbor type I herpes infection. Current literature contains a large body of clinical and experimental data regarding the detection of herpes infection; their amount is significantly lower in the works devoted to ischemic and traumatic brain injury. Zis *et al.* have described the case of ischemic stroke in the presence of herpetic encephalitis, and provide references for six similar cases [12]. In the work [5], a few cases of herpetic encephalitis in the presence of stroke were described. In both [5] and [12], however, the researchers note that there is a problem in testing for and identifying HSV, and they emphasized that accurate serologic diagnostics is needed because the MRI image of both pathologies is very similar. In fact, in regarding this pathology, there is significant variation of laboratory results published by different authors. Some studies have revealed that the issue is with testing (detection of viruses), specifically, the choice of test kits containing antibodies to VZV and HSV, since ELISA assay may give conflicting data [3]. Therefore, the authors emphasize the need for more thorough diagnosis and verification of neuroinfection symptoms of herpes encephalitis and stroke. In our work, within the first 2 weeks, the PCR was negative, with sufficient quantities of IgG found [10]. The results of our clinical and laboratory study therefore has revealed the different sensitivities of assays at the early stages of viral infection in asymptomatic patients. Dot-Elisa was more sensitive and, hence, a more suitable assay than was PCR.

According to our data, herpes infection should be considered one of the therapeutic targets in the management of post-stroke complications. In our study, the use of acyclovir

suppressed viral reproduction and the further development of infection. However, the primary lesion in the brain persisted. It seems that this antiviral drug only suppresses the reproduction of virions. Still, acyclovir can be used to prevent the development of HSV-1 infection in brain stroke. However, further search for drugs that are more effective is warranted. What is more, early diagnosis and treatment can begin with considering the results of serological tests for the detection of antigens to *Herpes viridae*. It should be noted that our results are important, not only for herpes virus infection, but may be useful for other viral, fungal and bacterial infections. A study of immunological response to viral neuroinfections in CNS lesions would be promising in engendering early diagnosis and treatment.

CONCLUSIONS

1. Hemorrhagic stroke is a pathogenic factor of HSV-I reactivation.
2. Dot-Elisa is a more sensitive and suitable assay for detecting the early stages of HSV-I infection, than is PCR.
3. The use of acyclovir in the experimental stroke suppressed HSV-I reproduction and further development of infection.

REFERENCES

1. Abbott A.L., Nicolaides A. N. Improving outcomes in patients with carotid stenosis. Call for better research opportunities and standards. *Stroke*, 46, 7, 2015.
2. Franklin K., Paxinos G. (2001). *The mouse brain in stereotaxic coordinates*. San Diego: Academic Press.
3. Grose C. Biological plausibility of a link between arterial ischemic stroke and infection with varicella-zoster virus or herpes simplex virus. *Circulation*, 133, 695, 2016.
4. Gumenyuk A.V. et al.: Mutual influence of herpes virus infection activate circulation impairment on the state of brain cells. *Biopolymers and Cell*, 32, 126, 2016.
5. Hara Y. et al.: Herpes simplex encephalitis initially presented with parietal cortex lesions mimicking acute ischemic stroke: A case report. *Rinsho Shinkeigaku*, 56, 104, 2016.
6. Joshi P.: Multiple strokes associated with herpes simplex virus type-2 infection: case report. *J. Neurovirol.*, 22, 251, 2016.
7. Kalkonde Y.V., D et al.: Stroke is the leading cause of death in rural Gadchiroli, India. A prospective community-based study. *Stroke*, 46, 1764, 2015.
8. Savosko S.I. et al.: Features of Histostructural Changes in Rat Cerebral Cortex in Hemorrhagic Stroke Modeling. *International Journal of Physiology and Pathophysiology*, 4, 2, 113, 2013. <http://www.dl.begellhouse.comru/journals/6ec4ba27650016b1,3301bbf015c9d744,53bfe80d71ecdda.html>
9. Snider, S.B. et al.: Hemorrhagic and ischemic stroke secondary to herpes simplex virus type 2 meningitis and vasculopathy. *J Neurovirol.*, 20, 419, 2014.
10. Terlizzi V., et al.: Primary herpes virus infection and ischemic stroke in childhood: a new association? *J. Clin. Neurosci.*, 21, 1656, 2014.
11. Zhang H., Li X.: Correlation between inflammatory factors and post-stroke pneumonia in diabetic patients. *Exp. Ther. Med.*, 1, 105, 2013.
12. Zis P., et al.: Herpes simplex virus type 2 encephalitis as a cause of ischemic stroke: case report and systematic review of the literature. *J. Stroke Cerebrovasc Dis.*, 25, 335, 2016.