

Current Issues in Pharmacy and Medical Sciences

Formerly ANNALES UNIVERSITATIS MARIAE CURIE-SKŁODOWSKA, SECTIO DDD, PHARMACIA

journal homepage: <http://www.curipms.umlub.pl/>

An unusual origin of the right subclavian artery – arteria lusoria

AGNIESZKA MOCARSKA¹, MIROSLAW SZYLEJKO², ELZBIETA STAROSLAWSKA¹, FRANCISZEK BURDAN^{1,3}¹ St. John's Cancer Centre; Lublin, Poland² Regional Railway Hospital in Lublin, Poland³ Department of Anatomy, Medical University of Lublin, Lublin, Poland**ARTICLE INFO**Received 8 December 2014
Accepted 10 December 2014**Keywords:**aortic arch,
subclavian artery,
arteria lusoria,
angioCT,
anatomical variation.**ABSTRACT**

The aortic arch usually gives off three major arterial branches: the brachiocephalic trunk, the left common carotid artery and the left subclavian artery. The most frequently occurring developmental variations of arterial trunks origins are a joined brachiocephalic and left common carotid artery origin, the left vertebral artery branching from the aortic arch, a double aortic arch, and a change of sequence of branching arteries. The current report presents the rare asymptomatic situation of the right subclavian artery originating as the last individual branching from the aortic arch. This abnormality was accidentally discovered in a computed tomography examination of a 69-year old male patient. The examination showed that the artery went towards the neck posteriorly from the trachea. The anatomical anomaly was interpreted as being an *arteria lusoria*.

In 83% of all cases, the aortic arch gives off three major arterial branches: the brachiocephalic trunk (which divides into the right subclavian artery and the right common carotid artery), the left common carotid artery and the left subclavian artery [1,3,8,23]. The congenital variations of the aortic arch constitute less than 1% of all congenital defects of the cardiovascular system, and the frequency of their occurrence is not correlated with gender or geographic environment [23]. The current report presents the rare asymptomatic situation of right subclavian artery originating as the last individual branching from the aortic arch.

CASE STUDY

A man aged 69, a long time smoker, reported for internistic consultation prior to a planned transurethral resection of the prostate. The patient had not required chronic cardiologic treatment so far, but the patient had been treated for arteriosclerosis: three years before, he had undergone a surgery of endovascular stent-graft implantation in the abdominal aorta due to aneurysm. In the interview, the patient reported

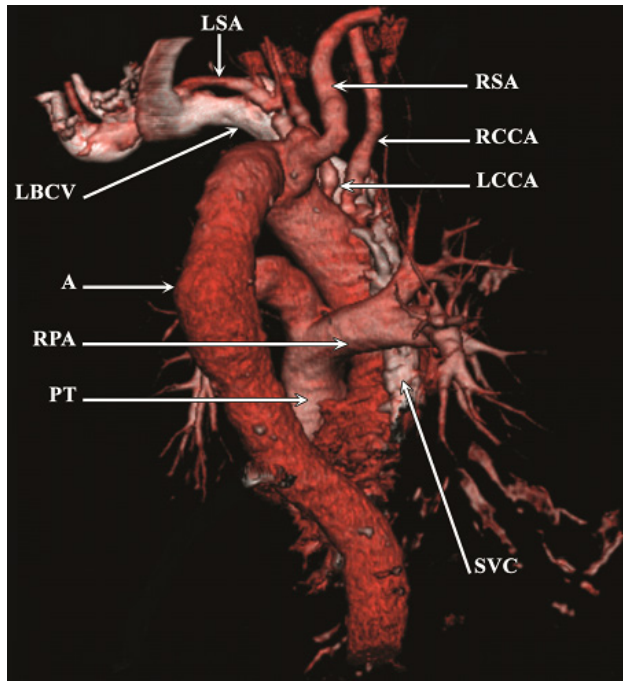
palpitations and decreased exercise tolerance, but a physical examination did not reveal any abnormalities, while a chest X-ray image showed dilatation of the thoracic aorta. No deviations were found in standard laboratory parameters of blood serum.

A chest angioCT examination – conducted on a CT scanner (Siemens Somatom Emotion 6) revealed an anatomical anomaly involving the aortic arch. The right subclavian artery originated individually as the last branching of the arch (Fig. 1). Above the artery origin, it was bent and aneurysmally dilated to 22 mm, then it went slantingly upwards behind the trachea. The anatomical variation was identified as being an *arteria lusoria*.

The chest angioCT examination also showed that the right common carotid artery branched individually in a location typical for a brachiocephalic trunk origin. In addition, left common carotid artery stenosis was found in the place of its origin, left subclavian artery stenosis was seen about 4 cm above its origin. What is more, ascending aorta dilatation up to 40 mm was noticed, and aortic arch dilatation up to 35 mm and aneurysmal dilatation of the descending aorta up to 46 mm (on a distance of 64 mm) was evident. Around paramural 9 mm thick thrombus and minute calcified arteriosclerotic plaques were seen along the full length of thoracic aorta.

Corresponding author

e-mail: fb3@wp.pl



A – aorta, LCCA – left common carotid artery, LSA – left subclavian artery, PR- pulmonary trunk, RBCV – right brachiocephalic vein, RCCA – right common carotid artery, RPA – right pulmonary artery

Figure 1. Posterior view of abnormal origin of the right subclavian artery (RSA; arteria lusoria) from the aortic arch (pseudo 3D reconstruction; CT post contrast examination)

DISCUSSION

Congenital developmental anomalies of the aortic arch are rare and may occur together with other congenital defects of the cardiovascular system. They are usually asymptomatic, do not require treatment and are accidentally detected, and for this reason, could be classified as incidental findings [4]. They can, however, give unspecific symptoms, dyspnea or intermittent claudication [9,10,19,25]. Arteria lusoria may cause dysphagia, and in rare cases, it may be the reason for the esophagus lumen narrowing, which can occur at any age [2,16,20]. A patient's treatment depends on the symptom intensity. In cases of serious dyspnea and breathing disorders or problems with swallowing, patients require surgical treatment [4,5].

The described developmental anomaly, with four arterial branches originating from the aortic arch, is caused by the right subclavian artery branching from the thoracic aorta instead of the right branchial artery IV [3]. This defect rarely occurs together with a common trunk of origin for both carotid arteries, and even less frequently with subclavian artery aneurysm. The frequency of occurrence of the described anomaly of the aortic arch is estimated to be from 0.4-2%. In 1735, Hunauld described the anomaly for the first time [21], and in 1794, Byford was the first to associate swallowing disorders with the defective origin and route of the subclavian artery course [13,20].

The number of vessels branching from the aortic arch may be variable and they can originate at different intervals between one another [12]. Congenital defects of aortic arch branching may be divided into the following five types [3]:

1. Single artery (the so-called 'carotid artery') ascending and separating into subclavian arteries and a trunk for the common carotid arteries.
2. Two arteries, giving off:
 - two brachiocephalic trunks, right and left, with each of these branching into the subclavian artery and the common carotid artery,
 - a single brachiocephalic trunk (right or left), in turn giving off the subclavian artery and the right and left common carotid arteries. The other subclavian artery originates individually.
3. Three arteries:
 - as individually originating subclavian arteries and the trunk of common carotid arteries,
 - a brachiocephalic trunk giving off a common carotid artery, with one subclavian artery and one vertebral artery originating individually.
4. Four arteries, subclavian arteries and common carotid arteries originating independently, in various order and at different intervals, as in the described case. In this type, individual origins of e.g. left vertebral artery, interior thoracic artery or the most inferior thyroid artery are also possible (with a normal brachiocephalic trunk).
5. Five and more branches, when the brachiocephalic trunk is either retained or not, and the right and left vertebral artery branch directly from the aortic arch.

A more modern division of congenital malformations of the aortic arch was suggested by Ergun (2013):

1. A normal aortic arch which has three branches: the brachiocephalic trunk, left common carotid artery and left subclavian artery.
2. An aortic arch with two branches, the first branch is the common trunk which is divided into the right subclavian artery, the right common carotid artery, the left common carotid artery, while the second branch is the left subclavian artery.
3. The left vertebral artery arises directly from the arch and the aortic arch has four branches: the brachiocephalic trunk, the left common carotid artery, the left vertebral artery and the left subclavian artery.
4. A common origin of the common carotid arteries, an arch with three branches: the right subclavian artery, a common trunk for the right common carotid artery and the left common carotid artery, and the left subclavian artery.
5. A common origin of the common carotids and an aberrant right subclavian artery, and an arch with three branches: the bicarotid trunk, the left and the right subclavian artery. The last being the last branch of the arcus aorta.
6. A common origin of common carotids and subclavian arteries, arch with two branches-avian from common stem for right and left common carotid artery, common stem for right and left subclavian artery.
7. The absence of the brachiocephalic trunk, an arch with four branches: the right subclavian artery, the right common carotid artery, the left common carotid artery and the left subclavian artery.
8. An additional branch coming from the arcus aorta (the 'thyroidea ima artery'), an arch with four branches: the

brachiocephalic trunk, the thyroidea ima artery, the left common carotid artery and the left subclavian artery [7].

The most frequent anatomical variation of aortic arch branching occurring in about 10-11% of the population is the joined origin of the brachiocephalic trunk and the left common carotid artery [1,14]. Lamers et al. (2004), on the basis of studies conducted upon 20 infants (computer tomography, magnetic resonance and EEG as well as hearing test) did not find any correlation between the presence of the anomaly and the occurrence of neurological defects as evaluated with EEG and a hearing test [14]. Clinical problems, however, may occur in adults, when stenosis or closure of the common trunk leads to a disruption of blood flow in three of four ways of blood supply to the brain. This may cause ischemic lesions [1].

Developmental variations of origin and course of arteries branching from the aortic arch may cause problems during vascular surgeries (e.g. in cases of brain artery aneurysms) or surgeries of the superior mediastinum and neck areas [6,17]. An example of a congenital anomaly of the aortic arch is the left vertebral artery branching directly from the aortic arch (this constituting about 16% of all aortic arch branching anomalies). This variation can be found accidentally, as it does not give any clinical symptoms. In rare cases, patients may experience sporadic dizziness [11,15,24].

Another rare variation in the origin of arteries branching from the aortic arch is the left common carotid artery and right vertebral artery branching from the brachiocephalic trunk with abnormal individual branching of the left vertebral artery from the aortic arch. Such arrangement of arteries may cause cerebral circulation disorders. The authors of this current study point out, similarly as in the above mentioned variation, that an awareness of the anatomical conditions is especially important in radiological diagnostics of intracranial aneurysms after subarachnoid hemorrhage [22]. Still one more rare anomaly is the individual branching of right vertebral artery from the proximal section of the descending aorta [18].

As can be seen in this report, anomalies can occur with benign or less benign influences upon the individual over time. Surgeons and medical personnel must, therefore, be aware of them.

REFERENCES

1. Azakie A. et al.: Common brachiocephalic trunk: strategies for revascularisation. *Ann. Thora. Surg.*, 67, 657-660, 1999.
2. Bennett A.L. et al.: Dysphagia lusoria. A late onset presentation. *World J. Gastroenterol.*, 19, 2433-2436, 2013 .
3. Bochenek A., Reicher M.: Zmienność położenia i przebiegu łuku aorty. W: *Anatomia człowieka. T. III. PZWL, Warszawa*, 108-170, 1993.
4. Burdan F. et al: Incidence of spinal perineurial (Tarlov) cysts among East-European patients. *PLoS One.* 8, e71514, 2013.
5. Derbel B. et al.: Aberrant right subclavian artery or arteria lusoria: a rare cause of dyspnea in children. *Ann. Vasc. Surg.*, 26, 1-4, 2012.
6. Dziekiewicz M. et al.: Variations in the anatomy of the branches of an aortic arch-two cases. *Acta Angiol.*, 12, 80-84, 2006.
7. Ergun E. et al.: Anatomical variations in branching pattern of arcus aorta: 64-slice CTA appearance. *Surg. Radiol. Anat.*, 35, 503-509, 2013.
8. Głowacki J. et al.: Technika obrazowania. Współistnienie koarktacji aorty z anomaliami tętnic łuku aorty na podstawie badań naczyniowych w 64-warstwowej tomografii komputerowej. *Kardiochir Torakochir. Pol.*, 5, 328-331, 2008.
9. Gnanapandithan K., et al.: Intermittent esophageal dysphagia: an intriguing diagnosis. Dysphagia lusoria. *Gastroenterology*, 146, 3-4, 2014.
10. Goray V.B. et al.: Aortic arch variation: a unique case with anomalous origin of both vertebral arteries as branches of the aortic arch distal to left subclavian artery. *Am. J. Neuroradiol.*, 26, 93-95, 2005.
11. Jayanthi V. et al.: Anomalous origin of the left vertebral artery. *Folia Morphol.*, 69, 258-260, 2010.
12. Kau T. et al.: Aortic development and anomalies. *Semin. Intervent. Radiol.*, 24, 141-152, 2007.
13. Kopp R. et al.: Surgical and endovascular treatment of symptomatic aberrant right subclavian artery (arteria lusoria). *Vascular.*, 15, 84-91, 2007.
14. Lamers L.J. et al.: The effect of common origin of the carotid arteries in neurologic outcome after neonatal ECMO. *J. Pediatr. Surg.*, 39, 532-536, 2004.
15. Lemke A.J. et al.: Anomalous origin of the right vertebral artery: review of the literature and case report of right vertebral artery: origin distal to the left subclavian artery. *Am. J. Neuroradiol.*, 20, 1318-1321, 1999.
16. Lesko M. et al.: One-step supraclavicular approach to the treatment of dysphagia lusoria. *J. Card. Surg.*, 29, 519-522, 2014.
17. Manyama M. et al.: A variant branching pattern of the aortic arch: a case report. *J. Card. Surg.*, 6, 29-31, 2011.
18. Mukkanavar S.B. et al.: Aberrant right vertebral artery from descending thoracic aorta. *Ann. Thorac. Surg.*, 96, 1074-1076, 2013.
19. Nastis K.I. et al.: Anatomical variations in the branches of the human aortic arch in 633 angiographies: clinical significance and literature review. *Surg.Radiol. Anat.*, 31, 319-323, 2009.
20. Okumuş M. et al.: A very rare cause of esophageal obstruction in a hypoxemic patient. *Turk. J. Gastroenterol.*, 25, 433-434, 2014.
21. Saeed G. et al.: Arteria lusoria aneurysm with truncus bicaroticus. *Tex. Heart Inst. J.*, 37, 602-607, 2010.
22. Shiva Kumar G.L. et al.: Anomalous branching pattern of the aortic arch and its clinical applications. *Singapore Med. J.*, 51, 182-183, 2010.
23. Stojanovska J. et al.: Embriology and imaging review of aortic arch anomalies. *J. Thorac. Imaging.* 27, 73-84, 2012.
24. Suresh R. et al.: Variations in the branching pattern of the aortic arch in three Trinidadians. *Vest Indian Med. J.*, 55, 351-353, 2006.
25. Türkvatani A. et al.: Congenital anomalies of the aortic arch: Evaluation with the use of multidetector computer tomography. *Korean J. Radiol.*, 10, 176-184, 2009.